

Correlation between the granulosa cell layer and active caspase-3 expression in ovarian follicles of *Tropidurus hispidus* and *T. semitaeniatus* (Squamata, Tropiduridae): immunohistochemical approach

Hellen da Silva Santos¹, Vanúzia Gonçalves Menezes², Eliza Maria Xavier Freire³, Maria Helena Tavares de Matos², Leonardo Barros Ribeiro¹

¹ Universidade Federal do Vale do São Francisco, Campus Ciências Agrárias, BR 407, Km 12, Lote 543, Projeto de Irrigação Nilo Coelho – S/N, C1, Núcleo de Ecologia Molecular, Laboratório de Morfofisiologia, CEP 56.300-000, Petrolina, PE, Brazil.

² Universidade Federal do Vale do São Francisco, Campus Ciências Agrárias, BR 407, Km 12, Lote 543, Projeto de Irrigação Nilo Coelho – S/N, C1, Laboratório de Biologia Celular, Citologia e Histologia, CEP 56.300-000, Petrolina, PE, Brazil.

³ Universidade Federal do Rio Grande do Norte, Campus Universitário Lagoa Nova, Centro de Biociências, Departamento de Botânica e Zoologia, Laboratório de Herpetologia, CEP 59072-970, Natal, RN, Brazil.

Recibido: 02 Junio 2020

Revisado: 20 Agosto 2020

Aceptado: 25 Agosto 2020

Editor Asociado: J. Goldberg

doi: 10.31017/CdH.2020.(2020-051)

ABSTRACT

The greatest threats to terrestrial reptiles are urban development and habitat modification. In this sense, a better understanding of folliculogenesis in these animals would be important to knowledge of reproductive biology. The aim of this study was to analyze the correlation between the thickness of the granulosa cell layer and the expression of the active caspase-3 protein in the previtellogenic and vitellogenic follicles of *T. hispidus* and *T. semitaeniatus*. Ovaries were used for histological (morphology and morphometry: thickness of granulosa layer) and immunohistochemical (active caspase-3 expression) analyses. The previtellogenic follicles of *T. hispidus* and *T. semitaeniatus* showed a thicker granulosa layer, with pyriform and small cells. The vitellogenic follicles had a monolayer of cuboid cells, and a thicker thecal layer. The thickness of the granulosa layer was significantly higher in the previtellogenic compared to the vitellogenic phase for both species. However, no differences were observed between the species. Active caspase-3 was observed in the pyriform and intermediate cells in previtellogenesis of *T. hispidus* and *T. semitaeniatus*. Nevertheless, no immunostaining was observed in the vitellogenic phase in both species. In conclusion, this study shows that the thickness of the granulosa cell layer is higher in the previtellogenic follicles compared to the vitellogenic follicles in the two *Tropidurus* species. Pyriform and intermediate cells from previtellogenic follicles show high expression of the protein, indicating that remodeling of the epithelium is associated with apoptosis. Finally, our results provide a scientific basis for assisted reproductive techniques and conservation actions to the reptiles in the future.

Key words: Apoptosis; Epithelium; Folliculogenesis; Lizards; Pyriform cells.

RESUMEN

Las mayores amenazas para los reptiles terrestres son el desarrollo urbano y la modificación del hábitat. En este sentido, una mejor comprensión de la foliculogénesis en estos animales sería importante para el conocimiento de la biología reproductiva. El objetivo de este estudio fue analizar la correlación entre el grosor de la capa de células de la granulosa y la expresión de la proteína caspase-3 activa en los folículos previtelogénicos y vitelogénicos de *T. hispidus* y *T. semitaeniatus*. Los ovarios se usaron para análisis histológicos (morfoloía y morfometría: grosor de la capa de la granulosa) e inmunohistoquímicos (expresión activa de caspase-3). Los folículos previtelogénicos de *T. hispidus* y *T. semitaeniatus* mostraron una capa de granulosa más gruesa, con células piriformes y pequeñas. Los folículos vitelogénicos tenían una monocapa de células cuboides y una capa tecal más gruesa. El grosor de la capa de granulosa fue significativamente mayor en la fase previtelogénica en comparación con la fase vitelogénica para ambas especies. Sin embargo, no se observaron diferencias entre las especies. Se observó caspase-3 activa en las células piriformes e intermedias en previtelogénesis de *T. hispidus* y *T. semitaeniatus*. Sin embargo, no se observó inmunotinción en la fase vitelogénica en ambas

especies. En conclusión, este estudio muestra que el grosor de la capa de células de la granulosa es mayor en los folículos previtelogénicos en comparación con los folículos vitelogénicos en las dos especies de *Tropidurus*. Las células piriformes e intermedias de folículos previtelogénicos muestran una alta expresión de la proteína, lo que indica que la remodelación del epitelio está asociada con la apoptosis. Finalmente, nuestros resultados proporcionan una base científica para técnicas de reproducción asistida y acciones de conservación para los reptiles en el futuro.

Palabras clave: Apoptosis; Epitelio; Foliculogénesis; Lagartos; Células piriformes.

Introduction

Lizards in the family Tropiduridae, particularly of the genus *Tropidurus*, are distributed along South America, and widely found in Brazil (Avila-Pires, 1995; Novaes-e-Silva and Araújo, 2008; Vitt *et al.*, 2008), especially in the Caatinga biome (Ribeiro and Freire, 2011). Among the tropidurid lizards, *Tropidurus hispidus* (Spix, 1825) and *Tropidurus semitaeniatus* (Spix, 1825) feed on arthropods, small vertebrates, and plant material (Ribeiro and Freire, 2011; Guedes *et al.*, 2017; Pergentino *et al.*, 2017), and serve as prey for invertebrates, such as spiders (Vieira *et al.*, 2012), and for vertebrates as snakes and other lizards (Silva *et al.*, 2013; Mikalauskas *et al.*, 2017). The temporal pattern of reproduction in Squamata in tropical regions is often associated with limiting environmental conditions, such as rainfall (Van Sluys *et al.*, 2002; Ávila *et al.*, 2008; Santos *et al.*, 2015), decreasing or ceasing the reproductive activities during the dry season (Fitch, 1982; Ribeiro *et al.*, 2012).

The greatest threats to terrestrial reptiles are thought to be agriculture, logging and harvesting followed by urban development and habitat modification (Böhm *et al.*, 2013). The development and implementation of genome banking strategies may be the only mechanism to prevent loss of genetic diversity and extinction in many reptile species in the future. Therefore, the acceleration of the biodiversity crisis is generating an imperative to develop assisted reproductive techniques to the reptiles (Clulow and Clulow, 2016). In this sense, a better understanding of folliculogenesis in these animals would be important to both the knowledge of reproductive biology and to provide a scientific basis for conservation actions (Ramírez-Bautista *et al.*, 2000; Young *et al.*, 2014).

The different phases of folliculogenesis (previtellogenic, vitellogenic, post-ovulatory or luteal phase, and follicular atresia) have already been characterized in some species of squamate reptiles

such as *Hemidactylus mabouia* (Moreau de Jonnés, 1818) (Moodley and Van Wyk, 2007), *Sceloporus grammicus* Wiegmann, 1828 (Lozano *et al.*, 2014), and *T. hispidus* and *T. semitaeniatus* (Santos *et al.*, 2015). The morphological changes in the granulosa and thecal layer, and in the ooplasm observed in the ovarian follicles during folliculogenesis were associated with vitellus deposition in lizards *H. mabouia* (Moodley and Van Wyk, 2007), *T. hispidus* and *T. semitaeniatus* (Santos *et al.*, 2015). At the end of previtellogenesis, the follicular epithelium undergoes remodeling and the intermediate and pyriform cells regress via apoptosis (Motta *et al.*, 1996).

Apoptosis is the main mechanism for the elimination of unnecessary cells during development and homeostasis in normal tissue (Liu *et al.*, 2017), and is mediated by a class of cysteine proteases called caspases (McIlwain *et al.*, 2013). Caspase-3 is a major executioner caspase that is cleaved at an aspartate residue to form the active caspase-3 enzyme (O'Donovan *et al.*, 2003). Active caspase-3 degrades multiple cellular proteins and is responsible for morphological changes (cell size reduction, cytoplasm condensation, membrane blebbing) and DNA fragmentation in cells during apoptosis (Hussein, 2005; McIlwain *et al.*, 2013). Recently, Tammaro *et al.* (2017) have demonstrated that the proform caspase-3 protein is present in previtellogenic follicle cells in the lizard *Podarcis siculus* (Rafinesque-Schmaltz, 1810). Their data indicated that the enzyme produced is maintained in the inactive proform until the end of the nurse function, and thereafter, activation occurs with consequent cell regression. However, there are no reports correlating intermediate and pyriform cell regression via apoptosis and the expression of active caspase-3 in *T. hispidus* and *T. semitaeniatus*.

Therefore, the aim of this study was to examine whether there is a correlation between histological (thickness of the granulosa cell layer) and functional

attributes (apoptosis, i.e. expression of the active caspase-3 protein) in the ovarian follicles of the lizards *T. hispidus* and *T. semitaeniatus* during the previtellogenic and vitellogenic phases.

Materials and methods

Source of ovarian tissue

Lizards from *T. hispidus* and *T. semitaeniatus* species were collected from the Ecological Station of Seridó (ESEC Seridó), Serra Negra do Norte municipality, state of Rio Grande do Norte, between October 2006 and May 2008. The specimens were dissected and their ovaries were removed and fixed in Bouin's solution for 4-6 h. Thereafter, histological and immunohistochemical analyses were performed at the Cell Biology/Cytology and Histology Laboratory of the Agrarian Sciences Campus of the Universidade Federal do Vale do São Francisco, Petrolina, state of Pernambuco.

Histological and morphometric analyses

A total of 30 pairs of ovaries (15 pairs for each species) were dehydrated using increasing concentrations of ethanol (Dinâmica, São Paulo, Brazil), clarified in xylene (Dinâmica) and embedded in paraffin (Dinâmica). The ovarian tissue was cut into 7 µm sections, and every section was mounted on glass slides and stained with hematoxylin and eosin (Vetec, São Paulo, Brazil). The slides were evaluated by light microscopy (Nikon, Tokyo, Japan; 400x magnification) and the images were obtained by using the Scope photo[®] software.

For morphological analysis, structures such as the granulosa and thecal layer cells, the vitelline membrane and the vitelline reservoir in the ooplasm were observed. The arrangement of these structures allowed us to determine the phases of folliculogenesis in these lizards (Santos et al., 2015). Only the follicles that showed intact granulosa cell layer and theca cells were analyzed. Thereafter, morphological analysis was performed using 20 follicles for each species (10 follicles for the previtellogenic phase and 10 for the vitellogenic phase). The thickness of the granulosa cell layer was measured by using the Image-Pro Plus[®] software. The follicles used for morphological and morphometric analyses were further used for immunohistochemistry assay.

Immunohistochemistry

Immunohistochemistry was performed according to

previous studies (Barberino *et al.*, 2017) with some modifications. Sections (5 µm thick) from each block were cut using a microtome (EasyPath, São Paulo, Brazil) and mounted in Starfrost glass slides (Knittel, Braunschweig, Germany). The slides were incubated in citrate buffer (Dinâmica) at 95°C in a decklocking chamber (Biocare, Concord, USA) for 40 min to retrieve antigenicity, and endogenous peroxidase activity was prevented by incubation with 3% H₂O₂ (Dinâmica) and methyl ethanol (QEEL, São Paulo, Brazil) for 10 min. Non-specific binding sites were blocked using 1% normal goat serum (Biocare) and diluted in phosphate-buffered saline (PBS; Sigma Aldrich Chemical Co., St. Louis, MO, USA). Subsequently, the sections were incubated in a humidified chamber for 90 min at room temperature with polyclonal anti-activated caspase-3 (pro apoptotic protein; 1:50; Santa Cruz Biotechnology). Thereafter, the sections were incubated for 30 min with MACH4 Universal HRP-polymer (Biocare). Protein localization was demonstrated with diaminobenzidine (DAB; Biocare), and the sections were counterstained with haematoxylin (Vetec) for 1 min. Negative control (reaction control) underwent all steps except the primary antibody incubation.

Images were acquired and files were saved in tagged-image file format (TIFF). Thereafter, the images were converted in RGB color model (it combines three primary colors, red, green, and blue, in various ways to create other colors; Liu *et al.*, 2006) by using the Adobe Photoshop[®] software (CC 2017 v18.0). Next, the RGB images were analyzed by using Image J software, and color separation was performed by automatically thresholding red-, green-, and blue-filtered gray-scale values of the image. This technique was applied to separate and differentially analyze DAB (brown)-stained antigen-positive cells/areas from hematoxylin (blue)-counterstained cells/areas (Ruifrok, 1997). The selected areas were then analyzed (number of pixels) by using Image-Pro Plus[®].

Statistical analysis

Data from the thickness of the granulosa cell layer (µm) in the phases of folliculogenesis were submitted to ANOVA and *t*-test for both intra- and interspecific comparisons. Spearman's correlation coefficient was used to verify the relationship between the thickness of the granulosa cell layer and active caspase-3 expression (pixels). The differences were considered to be statistically significant when $P < 0.05$.

Results

Morphological and morphometrical analysis of ovarian follicles

The ovarian follicles of *T. hispidus* and *T. semitaeniatus* were composed of an oocyte, granulosa and theca cells. The previtellogenic phase showed a thicker granulosa layer, which was characterized by the presence of pyriform cells (Fig. 1A) and intermediate cells. Small cells next to the vitelline membrane can also be observed (Fig. 1A). The granulosa layer is thinner in the vitellogenic phase, which showed a single layer of cuboid cells, contrasting with a thicker thecal layer (Fig. 1B).

The thickness of the granulosa cell layer was significantly higher in the pre-vitellogenic phase compared to the vitellogenic phase for both *T. hispidus* and *T. semitaeniatus* ($P < 0.05$, Table 1). However, no differences ($P > 0.05$) were observed between the species in both phases (pre-vitellogenic and vitellogenic).

Expression of active caspase-3 in the ovary

Immunohistochemistry analysis demonstrated the presence of active caspase-3 in the cytoplasm of pyriform cells (Fig. 2A, C and E) and intermediate cells (Fig. 2A, 3A, B and C) in follicles of the previtellogenic phase of *T. hispidus* and *T. semitaeniatus*. The intensity of immunostaining was 82.37 and 83.35 pixels for *T. hispidus* and for *T. semitaeniatus*, respectively. Nevertheless, no immunostaining was observed in any follicle in the vitellogenic phase in

both species (Fig. 2B, D and F). As the pyriform cells regressed, the intensity of active caspase-3 expression in the granulosa layer also decreased as a result of a gradual reduction of this protein. This finding could be observed in Figure 3B and C, which highlight the presence of the remaining intermediate cells of late previtellogenesis epithelium. However, although not statistically significant ($P = 0.05$), correlation between the thickness of granulosa layer and the intensity of protein expression (in pixels) was inversely proportional (*T. hispidus*: $r = -0.3952$, $P = 0.2582$; *T. semitaeniatus*: $r = -0.6833$, $P = 0.290$). The negative control is shown in figure 3D.

Discussion

This study showed that the thickness of the granulosa cell layer is higher in the pre-vitellogenic phase compared to the vitellogenic phase for both *T. hispidus* and *T. semitaeniatus*. Moreover, to our knowledge, this is the first study that demonstrates the expression of active caspase-3 protein in lizards. The protein was localized in previtellogenic follicular epithelia of the ovarian follicles of *T. hispidus* and *T. semitaeniatus*.

Four different phases of folliculogenesis have already been characterized for *T. hispidus* and *T. semitaeniatus*: previtellogenic, vitellogenic, post-ovulatory or luteal phase, and follicular atresia (Santos *et al.*, 2015). In this study, our purpose was to focus attention on issues related to the previtellogenic and vitellogenic follicles. At the beginning of

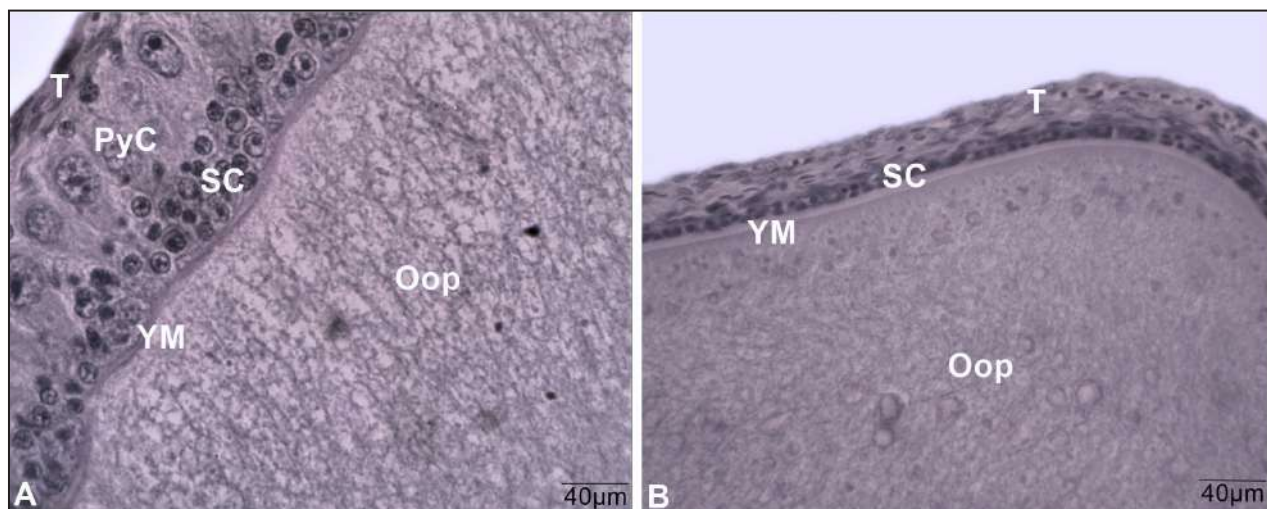


Figure 1. Ovarian follicle morphology in *Tropidurus semitaeniatus*: Polymorphic and multilayered epithelium with pyriform (PyC) and small cells (SC) in previtellogenic phase (A); the epithelium is composed by a single layer of small cuboid cells (SC) in the vitellogenic phase (B). T: theca layer, YM: yolk membrane, Oop: ooplasm. Scale bar: 40 μm .

Table 1. Thickness of the granulosa cell layer (mean \pm SD) of ovarian follicles of *Tropidurus hispidus* and *Tropidurus semitaeniatus*.

| Follicular phase | Thickness of the granulosa cell layer (μm) | |
|------------------|---|---------------------------------|
| | <i>Tropidurus hispidus</i> | <i>Tropidurus semitaeniatus</i> |
| Previtellogenic | 44.02 \pm 5.40 ^A | 35.77 \pm 8.98 ^A |
| Vitellogenic | 16.65 \pm 7.85 ^B | 19.43 \pm 5.21 ^B |

(A, B) Different letters in the same column indicate significant differences ($P < 0.05$).

the previtellogenic phase, the small cells from the granulosa layer start to differentiate, originating the intermediate cells and, following a further differentiation, into pyriform cells (Maurizii *et al.*, 1997; Maurizii *et al.*, 2000). In this phase, these pyriform cells, also called nurse cells, are responsible for the nutrition of the oocyte by sending it mRNA and organelles. Moreover, the vitellogenin, produced in the liver and carried via the circulation to the ovary, traverses the granulosa pyriform cells through an extracellular route (Klosterman, 1987), reaching the oocyte for future nutrition of the embryo to be developed (Santos *et al.*, 2015). By the end of previtellogenesis, pyriform cells transfer most of their cytoplasm and organelles to the growing oocyte, undergo an apoptotic process comprising chromatin clumping and internucleosomal fragmentation and regress (De Caro *et al.*, 1998). Therefore, in this study, regression of pyriform and intermediate cells could explain the lowest thickness of the granulosa cell layer in the vitellogenic phase compared to the previtellogenic phase observed for both species (*T. hispidus* and *T. semitaeniatus*). Similar result was demonstrated for the oviparous lizard *H. mabouia* (Moodley and Van Wyk, 2007).

To confirm the hypothesis that apoptosis was associated with regression of the pyriform and intermediate cells, we further evaluated active caspase-3 expression. Caspase-3 activation is necessary for initiation of apoptosis and regulation of processes such as membrane blebbing and internucleosomal DNA fragmentation (Hussein, 2005; McIlwain *et al.*, 2013). In this study, active caspase-3 was immunolocalized only in the granulosa cells of the previtellogenic follicles of *T. hispidus* and *T. semitaeniatus*. A previous study has also shown that the proform caspase-3 protein is present in previtellogenic follicular epithelia in the lizard *P. siculus* (Tammamo *et al.*, 2017). Moreover, these authors reported that mRNA

for caspase-3 is produced during the stem phase and stocked in the cell cytoplasm of small cells until differentiation in the pyriform nurse cells begins. These cells translate messengers but the enzyme produced is maintained in the inactive proform until the end of the nurse function. When the follicle reaches a diameter of about 1500 μm , it starts preparing for vitellogenesis and the epithelium becomes thinner in order to facilitate the uptake of vitellogenin by the oocyte (Motta *et al.*, 1996). At this time, the proform caspase-3 is activated with consequent pyriform cell regression (Tammamo *et al.*, 2017). These pyriform cells acquire the morphology typical of an apoptotic cell with chromatin being sent to the margin and condensed, plus membrane blebbings (Motta *et al.*, 1996). In agreement with these findings, we showed that pyriform cells undergo apoptosis at the end of previtellogenesis, which can be confirmed by the high intensity of active caspase-3 expression in these cells. Moreover, as the pyriform and intermediate cells regress with the progress of folliculogenesis, we did not observe expression of active caspase-3 in the vitellogenic follicles, thus, resulting in a follicular epithelium formed by a monolayer of small follicle cells, as previously reported in the lizard *P. siculus* (Motta *et al.*, 1995). The different fate of the cellular constituents could be a fundamental event that sustains the differentiation of both epithelium and oocyte in the lizards *T. hispidus* and *T. semitaeniatus*.

It is important to note that most research on lizard female reproduction has focused on the morphology of ovarian follicles (Klosterman, 1987; Motta *et al.*, 1995; Maurizii *et al.*, 2000; Lozano *et al.*, 2014; Santos *et al.*, 2015), whereas we have compared morphological and functional attributes (using a specific marker for apoptosis) in the follicles. As lizards, such as *T. hispidus* and *T. semitaeniatus*, provide valuable models for studies in ecology and evolution and offer a useful comparison for studies on other vertebrates (Hare and Cree, 2010), understanding their reproductive biology is the key to effectively use of genome storage for reptile conservation.

Collectively, our data shows that the thickness of the granulosa cell layer is higher in the previtellogenic follicles compared to the vitellogenic follicles for both *T. hispidus* and *T. semitaeniatus*. Moreover, pyriform and intermediate cells from previtellogenic follicles show high expression of the active caspase-3 protein, indicating that the remodeling of the epithelium is associated with apoptosis, which could be the result of a functional adaptation in these spe-

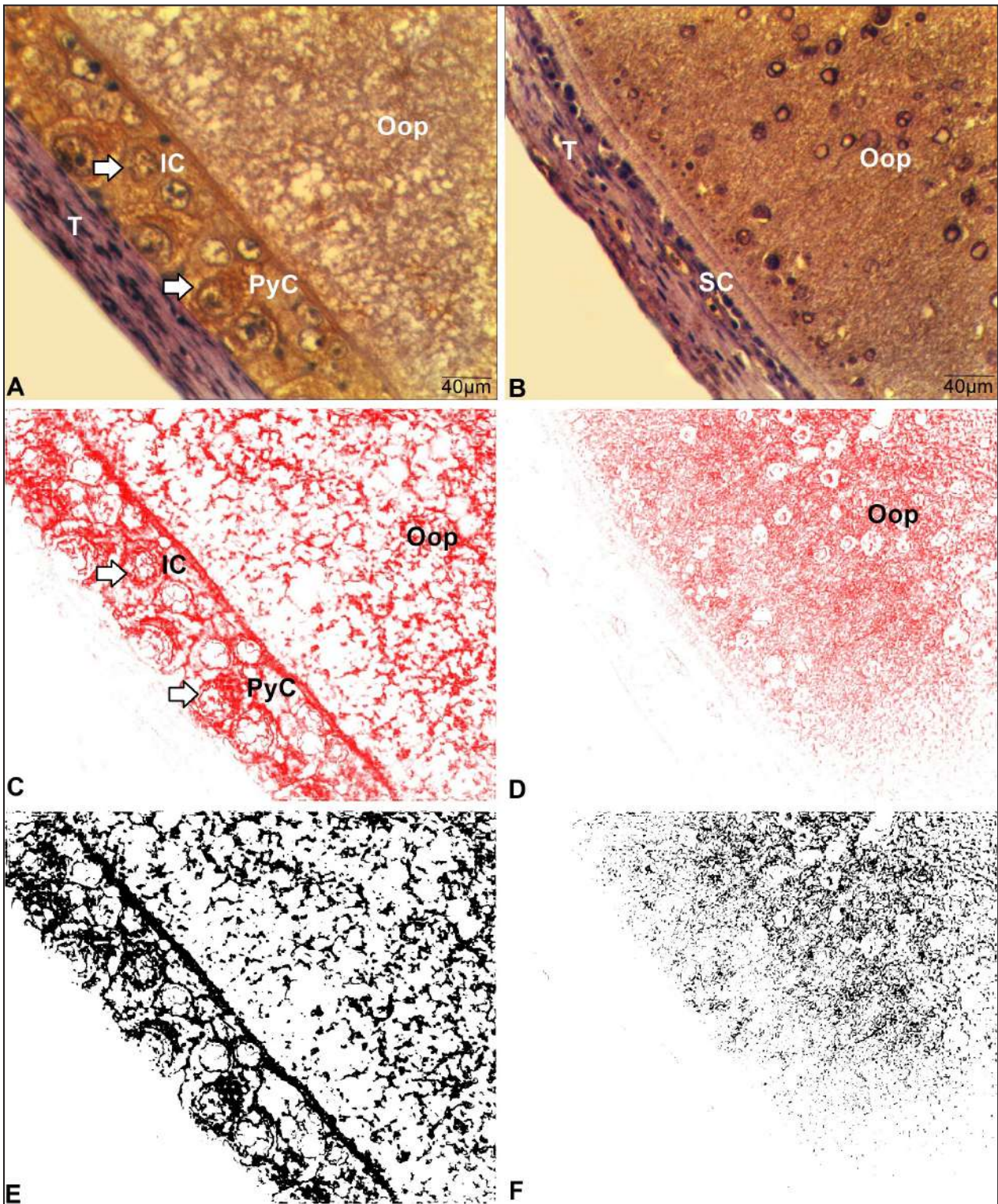


Figure 2. Active caspase-3 localization in follicular epithelial cells of lizards. Pyriform (PyC) and intermediate cells (IC) of previtellogenic follicles of *Tropidurus hispidus* are intensely labeled (A). Vitellogenic epithelium of *Tropidurus semitaeniatus* showing small cells (SC) without immunostaining (B). Note that theca cells are unlabeled in both phases of folliculogenesis (A and B). The same follicles (previtellogenic and vitellogenic follicles) after color separation to highlight DAB (brown)-stained antigen-positive cells/areas (C and D). Images were converted in a gray scale by using threshold tool to quantify the intensity (pixels) of the active caspase-3 expression (E and F). Arrows indicate positivity for active caspase-3 (A and C). T: Theca layer; Oop: Ooplasma. Scale bar: 40 μ m.

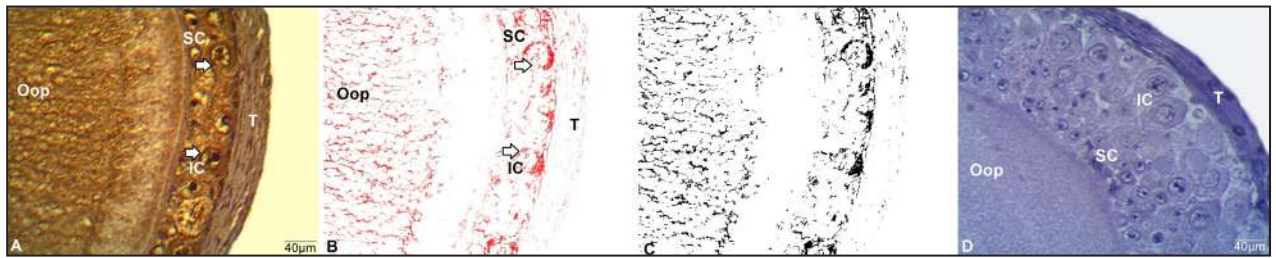


Figure 3. Immunolocalization of active caspase-3 in follicular epithelial cells of *Tropidurus hispidus* in the previtellogenic phase (A), highlighting that with the progression of pyriform cells regression, the intensity of protein expression reduced (B and C). Negative control (D). Arrows indicate greater positivity for active caspase-3 in intermediate cells. IC: Intermediate cells; SC: Small cells; T: Theca layer; Oop: Ooplasm. Scale bar: 40 µm.

cies. Finally, our results provide a scientific basis for assisted reproductive techniques and conservation actions to the reptiles in the future.

Acknowledgements

We thank the Instituto Brasileiro do Meio Ambiente e Recursos Naturais Renováveis (IBAMA) for the specimen collection licenses (collection permit 206/2006 and Process 02001.004294/03-15). HSS holds a scholarship from the Coordenação de Aperfeiçoamento de Pessoal de Nível Superior (CAPES), and MHTM is supported by a grant from the Conselho Nacional de Desenvolvimento Científico e Tecnológico (CNPq).

Literature cited

- Ávila-Pires, T.C.S. 1995. Lizards of Brazilian Amazonia (Reptilia: Squamata). *Zoologische Verhandlungen (Leiden)* 299: 1-706.
- Ávila, R.W.; Cunha-Avellar, L.R. & Ferreira, V.L. 2008. Diet and reproduction of the lizard *Tropidurus etheridgei* in rocky areas of central Brazil. *Herpetological Review* 39: 430-433.
- Barberino, R.S.; Menezes, V.G.; Ribeiro, A.E.A.S.; Palheta-Jr, R.C.; Xuenjun, J.; Smitz, J.E.J. & Matos, M.H.T. 2017. Melatonin protects against cisplatin-induced ovarian damage in mice via the MT1 receptor and antioxidant activity. *Biology of Reproduction* 96: 1244-1255.
- Böhm, M.; Collen, B.; Baillie, J.E.M.; Bowles, P.; Chanson, J.; Cox, N.; Zug, G. 2013. The conservation status of the world's reptiles. *Biological Conservation* 157: 372-385.
- Clulow, J. & Clulow, S. 2016. Cryopreservation and other assisted reproductive technologies for the conservation of threatened amphibians and reptiles: bringing the ARTs up to speed. *Reproduction, Fertility and Development* 28: 1116-1132.
- De Caro, M.; Indolfi, P.; Iodice, C.; Spagnolo, M.S.; Tammaro, S. & Motta, C.M. 1998. How the ovarian follicles of *Podarcis sicula* recycles the DNA of its nurse regressing follicle cells. *Molecular Reproduction and Development* 51: 421-429.
- Fitch, H.S. 1982. Reproductive cycles in tropical reptiles. *Occasional Papers of the Museum of Natural History* 96: 1-53.
- Guedes, T.B.; Miranda, F.H.B.; Menezes, L.M.N.; Pichorim, M. & Ribeiro, L.B. 2017. Avian predation attempts by *Tropidurus hispidus* (Spix, 1825) (Reptilia, Squamata, Tropiduridae). *Herpetology Notes* 10: 45-47.
- Hare, K.M. & Cree, A. 2010. Incidence, causes and consequences of pregnancy failure in viviparous lizards: implications for research and conservation settings. *Reproduction, Fertility and Development* 22: 761-770.
- Hussein, M.R. 2005. Apoptosis in the ovary: molecular mechanisms. *Human Reproduction* 11: 162-177.
- Klosterman, L.L. 1987. Ultrastructural and quantitative dynamics of the granulosa of ovarian follicles of the lizard *Gerrhonotus coeruleus* (family Anguillidae). *Journal of Morphology* 192: 125-144.
- Liu, P.F.; Hu, Y.; Kang, B.H.; Tseng, Y.K.; Wu, P.C.; Liang, C.C.; Shu, C.W. 2017. Expression levels of cleaved caspase-3 and caspase-3 in tumorigenesis and prognosis of oral tongue squamous cell carcinoma. *PLoS ONE* 12: e0180620.
- Liu, B.; Wang, W. & Fang, X. 2006. Automatic extraction of positive cells in tumor immunohistochemical pathology image based on YCbC. *Proceedings of the 6th World Congress on Intelligent Control and Automation* 6: 21-23.
- Lozano, A.; Ramírez-Bautista, A. & Uribe, M.C. 2014. Oogenesis and ovarian histology in two populations of the viviparous lizard *Sceloporus grammicus* (Squamata: Phrynosomatidae) from the central Mexican Plateau. *Journal of Morphology* 275: 949-960.
- Manes, M.E.; Noriega, T.; Casal, F.C. & Apichela, S. 2007. Ovarian changes during the reproductive cycle of the *Tupinambis merianae* lizard raised in a temperate environment. *Cuadernos de Herpetología* 21: 21-29.
- Maurizii, M.G.; Alibardi, L. & Taddei, C. 2000. Organization and characterization of the keratin cytoskeleton in the previtellogenic ovarian follicle of the lizard *Podarcis sicula*. *Molecular, Reproduction and Development* 57: 159-166.
- Maurizii, M.G.; Saverino, O. & Taddei, C. 1997. Cytokeratin cytoskeleton in the differentiating ovarian follicle of the lizard *Podarcis sicula*. *Molecular, Reproduction and Development* 48: 536-542.
- McIlwain, D.R.; Berger, T. & Mak, T.W. 2013. Caspase functions in cell death and disease. *Cold Spring Harbor Perspectives in Biology* 5:a008656.
- Mikalaukas, J.S.; Santana, D.O. & Ferrari, S.F. 2017. Lizard predation *Tropidurus hispidus* (Squamata, Tropiduridae) by false coral snake *Oxyrhopus trigeminus* (Squamata, Dipsadidae) in the Caatinga, in northeastern Brazil. *Pesquisa e Ensino em Ciências Exatas e da Natureza* 1: 60-67.
- Moodley, G.K. & Van Wyk, J.H. 2007. Folliculogenesis and ovarian histology of the oviparous gecko, *Hemidactylus mabouia* (Sauria: Gekkonidae). *African Journal of Herpetology* 56: 115-135.

- Motta, C.M.; Scanderberg, M.C.; Filosa, S. & Andreuccetti, P. 1995. Role of pyriform cells during the growth of oocytes in the lizard *Podarcis sicula*. *Journal of Experimental Zoology* 273: 247-256.
- Motta, C.M.; Filosa, S. & Andreuccetti, P. 1996. Regression of the epithelium in late previtellogenic follicles of *Podarcis sicula*: a case of apoptosis. *Journal of Experimental Zoology* 276: 233-241.
- Novaes-e-Silva, V. & Araújo, A.F.B. 2008. Ecologia dos lagartos brasileiros. Technical Books, Rio de Janeiro.
- O'Donovan, N.; Crown, J.; Stunell, H.; Hill, A.D.; McDermott, E. & O'Higgins, N. 2003. Caspase 3 in breast cancer. *Clinical Cancer Research* 9: 738-742.
- Pergentino, H.E.S.; Nicola, P.A.; Pereira, L.C.M.; Novelli, I.A. & Ribeiro, L.B. 2017. A new case of predation on a lizard by *Tropidurus hispidus* (Squamata, Tropiduridae), including a list of saurophagy events with lizards from this genus as predators in Brazil. *Herpetology Notes* 10: 225-228.
- Ramírez-Bautista, A.; Balderas-Valdivia, C. & Vitt L.J. 2000. Reproductive ecology of the whiptail lizard *Cnemidophorus lineatissimus* (Squamata: Teiidae) in a tropical dry forest. *Copeia* 2000: 712-722.
- Ribeiro, L.B. & Freire, E.M.X. 2011. Trophic ecology and foraging behavior of *Tropidurus hispidus* and *Tropidurus semitaeniatus* (Squamata, Tropiduridae) in a caatinga area of northeastern Brazil. *Iheringia, Série Zoologia* 101: 225-232.
- Ribeiro, L.B.; Silva, N.B. & Freire, E.M.X. 2012. Reproductive and fat body cycles of *Tropidurus hispidus* and *Tropidurus semitaeniatus* (Squamata, Tropiduridae) in a caatinga area of northeastern Brazil. *Revista Chilena de Historia Natural* 85: 307-320.
- Ruifrok, A.C. 1997. Quantification of immunohistochemical staining by color translation and automated thresholding. *Analytical and Quantitative Cytology and Histology* 19: 107-113.
- Santos, H.S.; Santos, J.M.S.; Matos, M.H.T.; Silva, N.B.; Freire, E.M.X. & Ribeiro, L.B. 2015. Ovarian follicular cycle of *Tropidurus hispidus* and *Tropidurus semitaeniatus* (Squamata: Tropiduridae) in a semiarid region of Brazil. *Zoologia: an international journal for zoology* 32: 86-92.
- Silva, E.A.P.; Santos, T.D.; Leite, G.N. & Ribeiro, L.B. 2013. *Tropidurus hispidus* (Squamata: Tropiduridae) and *Leptodactylus cf. fuscus* (Anura: Leptodactylidae) as prey of the teiid lizards *Salvator merianae* and *Ameiva ameiva*. *Herpetology Notes* 6: 51-53.
- Tammaro, S.; Simoniello, P.; Ristoratore, F.; Coppola, U.; Scudiero, R. & Motta, C.M. 2017. Expression of caspase 3 in ovarian follicle cells of the lizard *Podarcis sicula*. *Cell Tissue Research* 367: 397-404.
- Van Sluys, M.; Mendes, H.M.A.; Assis, V.B. & Kiefer, M.C. 2002. Reproduction of *Tropidurus montanus* Rodrigues, 1987 (Tropiduridae), a lizard from a seasonal habitat of south-eastern Brazil, and a comparison with other *Tropidurus* species. *Herpetological Journal* 12: 89-97.
- Vieira, W.L.S.; Gonçalves, M.B.R. & Nóbrega, R.P. 2012. Predation on *Tropidurus hispidus* (Squamata: Tropiduridae) by *Lasiadora klugi* (Aranea: Theraphosidae) in the semiarid caatinga region of northeastern Brazil. *Biota Neotropica* 12: 263-265.
- Vitt, L.J.; Magnusson, W.E.; Ávila-Pires, T.C. & Lima, A.P. 2008. Guia de lagartos da Reserva Adolpho Ducke, Amazônia Central. Áttema Design Editorial, Manaus.
- Young, C.; Curtis, M.; Ravida, N.; Mazotti, F. & Durrant, B. 2014. Development of a sperm cryopreservation protocol for the Argentine black and white tegu (*Tupinambis merianae*). *Reproduction, Fertility and Development* 26: 168-169.