

Monensin poisoning in buffalo feedlot from Argentina

García, E.N.¹; Pistán, M.E.¹; Lértora, W.J.¹; Mastrantonio, G.E.^{2,3}; Cholich, L.A.^{1,3}

¹Fac.Vet.Sci., Nat.North.Univ., Cabral 2139, Corrientes 3400, Argentina. ²Fac. Exact Sci., Nat.Univ.La Plata, Buenos Aires. ³Nat.Sci.Res.Cou.(CONICET), Argentina. Subs.Secret.Ciencia & Técnica N°17B007. Present.36° Jorn.Arg. Toxicol.2018, Córdoba, Argentina.
E-mail: garciaenicolos@gmail.com

Abstract

García, E.N.; Pistán, M.E.; Lértora, W.J.; Mastrantonio, G.E.; Cholich, L.A.: Monensin poisoning in buffalo feedlot from Argentina. *Rev. vet. 31: 1, 38-41, 2020.* The aim of this paper was to describe a case of accidental monensin poisoning of feedlot domestic buffalo (*Bubalus bubalis*) in northeastern Argentina. Clinical signs included anxiety facie with orthopneic position, teeth grinding, diarrhea, muscular weakness, depression and recumbency. In monensin intoxicated animals, a significant increase of creatine phosphokinase and aspartate aminotransferase was observed. At *postmortem* examination, buffaloes consistently had pale areas that were irregularly distributed in cardiac and skeletal muscles, hydrothorax, congestion and oedema of the lung. Degeneration and necrosis of the myocardium and skeletal muscle was observed by histological examination. Feed analysis revealed toxic levels of monensin; therefore, ionophore toxicosis was diagnosed. Accordingly, it is required great caution when feeding buffaloes with monensin used as a feed additive.

Key words: buffaloes, cardiomyopathy, myotoxicosis, monensin, toxicity.

Resumen

García, E.N.; Pistán, M.E.; Lértora, W.J.; Mastrantonio, G.E.; Cholich, L.A.: Intoxicación con monensina en un feedlot de búfalos de Argentina. *Rev. vet. 31: 1, 38-41, 2020.* El objetivo de este trabajo fue describir un envenenamiento accidental por monensina en búfalos domésticos (*Bubalus bubalis*) pertenecientes a un feedlot ubicado en la región nordeste de Argentina. Los signos clínicos incluyeron ansiedad, posición ortopneica con rechinar de dientes, diarrea, debilidad muscular, depresión y recumbencia. En los animales expuestos a monensina se observaron aumentos significativos de creatin fosfoquinasa y aspartato aminotransferasa. A la necropsia, los búfalos presentaron áreas pálidas de distribución irregular, hidrotórax, congestión y edema pulmonar. Al examen histológico se observó degeneración y necrosis de músculos cardíaco y esquelético. El análisis del alimento reveló niveles tóxicos de monensina, por lo cual se diagnosticó una toxicosis por ionóforos. A pesar de los efectos positivos de la monensina como fuente de alimento de los animales, se debe requerir un mayor nivel de precaución al alimentar búfalos con ionóforos.

Palabras clave: búfalos, miocardiopatía, miotoxicosis, monensina, toxicidad.

INTRODUCTION

Monensin is an ionophore produced by *Streptomyces cinnamonensis*. This agent has been used as coccidiostat and as antibiotic ⁷. In the last years, it has been incorporated as feed additive in order to improve performance in livestock production systems ¹⁰. Despite the widespread use of monensin, accidental intoxications in cattle ², sheep ^{11,12}, horse ^{5,15} and buffalo ^{18,19} were reported in the literature. Monensin intoxication may occur due to mixing errors during feed preparation and its use in non-recommended species ¹⁴.

The susceptibility to intoxication by monensin is variable and depends on each animal species. Horses

are the most susceptible species to ionophore toxicity and fish, the most tolerant to exposure to high levels of ionophores ^{5,8}. Clinical signs depends on the amount of monensin ingested, and the predominant lesion is muscle degeneration ^{2,16,18}.

In the last years, the expansion of agriculture, along with the search for enhanced efficiency in livestock production has led to increased use of drugs, as strategies to improve profitability. In this context, antibiotics have contributed substantial improvement in the efficiency of intensive systems, which has led to an almost massive use over the last years ⁶.

This paper describes a case of acute monensin poisoning in domestic buffalo (*Bubalus bubalis*), in a feedlot from north-eastern Argentina after accidental feeding. In addition to gross and microscopic lesions,

clinical and epidemiological aspects of the disease have been identified.

MATERIAL AND METHODS

The case occurred in a small farm in the rural area of the town of Riachuelo, 18 km away from Corrientes city, in December 2017. The farm was visited to investigate an outbreak in buffaloes reported by its owner. The feedlot composed of 174 water buffalo calves of the Mediterranean breed with an average weight of 180 kg, received concentrated food and alfalfa *ad-libitum*.

The farmer reported that some days before, concentrated food given to calves (without monensin), was changed by another commercial product, from another company, which lacked the corresponding product data-sheet. Within the first week of being fed with the new concentrate product, 15 of the animals showed reluctant to move and marked agitation. Within 10 days, 30 buffaloes became ill and died.

The first measure taken was to suspend feeding with the concentrate product. Despite of, animals continued to die during ten days. The ill animals were clinically examined. Clinical signs were recorded and monensin intoxication was suspected. Blood samples were collected from 10 animals which seemed to be the most affected ones, to determine serum enzyme activities. Necropsy was performed in 5 animals. Heart, liver, lung, kidney, and skeletal and cardiac muscle were collected, fixed in 10% formalin for 24 h, processed for histology, stained with haematoxylin-eosin (HE) and examined by light microscopy.

Three samples of the suspect feed were collected from three equally spaced points along the feeding system and a single aliquot was analyzed. The concentration of monensin was determined using a spectrophotometry method⁴, and results were expressed in mg/kg.

RESULTS

Mortality and lethality rates of the observed animals were 0.17 and 1.0, respectively, with 30 dead buffaloes being recorded. Clinical signs found ranged from anxiety facie with orthopneic position, diarrhea and teeth grinding, to muscular weakness and instability. Lastly, clinical signs progressed to severe depression and recumbency.

The quantitative analysis of food samples revealed 65 ± 6 mg/kg of sodium monensin in the total mix. Table 1 shows the biochemical parameters. Affected animals showed a significantly high values in aspartate aminotransferase and creatine phosphokinase activity ($p < 0.05$), compared to healthy buffaloes (without clinical signs).

Necropsy revealed that the cardiac and skeletal muscles of animals with clinical signs of intoxication had irregularly distributed pale areas, congestion and edema of the lung, along with hydrothorax (Figure 1).

The main histological lesions were found in skeletal (Figure 2) and cardiac muscles (Figure 3); degenerative

Table 1. Changes of serum creatine phosphokinase (CPK) and aspartate aminotransferase (AST) activities in buffaloes intoxicated with monensin.

group	CPK (U/L)	AST (U/L)
intoxicated	30115 \pm 1703*	106 \pm 20*
control	641 \pm 205	19.4 \pm 7.9

*Data are expressed as mean \pm standard deviation (SD). Values are statistically significant at * $p < 0.05$.

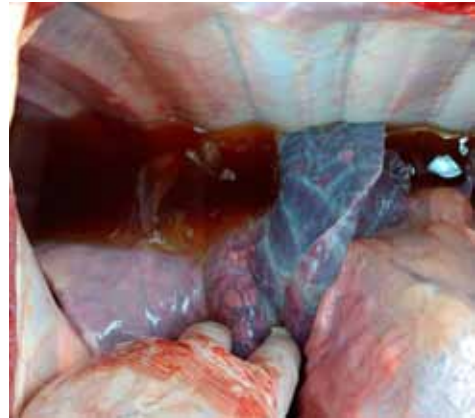

Figure 1. Interstitial pulmonary edema and hydrothorax from buffalo poisoned by monensin.

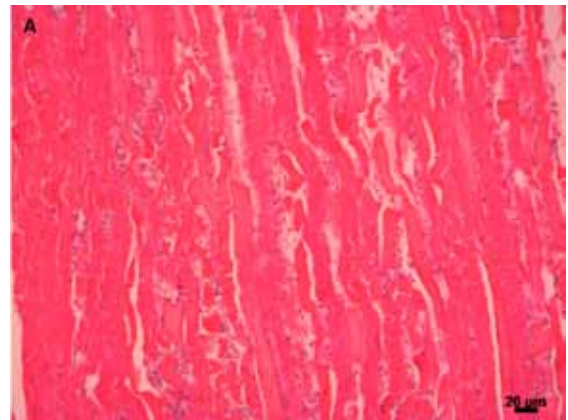


Figure 2. Histopathology of skeletal muscle from buffalo poisoned with monensin. Multifocal polyphasic segmental necrosis in muscle fibers. HE, scale 20 μ .

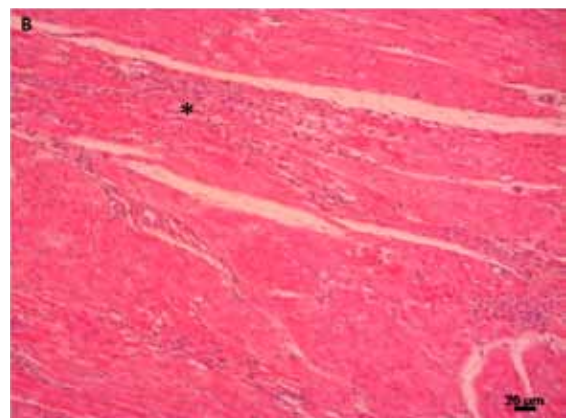


Figure 3. Histopathology of myocardium from buffalo poisoned with monensin. Multifocal myofiber necrosis and fibrosis (asterisk). HE, scale 20 μ .

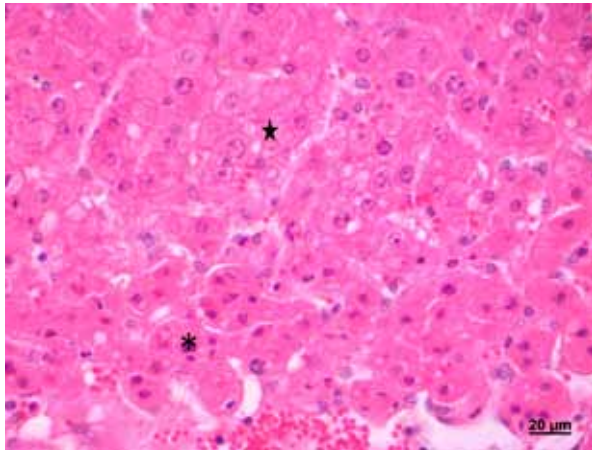


Figure 4. Histopathology of liver from buffalo poisoned with monensin. Centrilobular necrosis (asterisk) and microvesicular fatty change in periportal liver cells (star). HE, scale 20 μ .

and necrotic changes were observed, with cytoplasmic hypereosinophilia, loss of striations and fragmentation of muscle fibers. All cases had focal mononuclear infiltration of varying degrees.

In affected animals, the liver showed marked hepatocellular vacuolization, as well as centrilobular coagulative necrosis (Figure 4). The lungs showed congestion, and alveolar and interstitial oedema. Presence of cylindrical and hyaline content was observed in Bowman's space and in the renal tubule. The remaining tissues showed no histological changes.

DISCUSSION

Diagnosis of experimental and accidental monensin toxicosis is based on clinical signs, pathological lesions and biochemical changes of serum parameters^{8, 18-21}. In this study, the presence of monensin was evidenced in food samples using a simple and effective spectrophotometric method for ionophore quantitative measurement.

In cattle, the use of monensin is authorised for fattening, up to a concentration of 50 mg/kg feed¹⁹. In this work, the amount of monensin was determined in feed samples. This result shows the importance of monitoring nutrients and aggregates of chemical composition in the food offered to these animals.

The toxic dose of monensin for buffaloes has been reported to be 5 mg/kg¹⁸ and the LD50 for cattle was estimated within a range of 21.9 up to 80 mg/kg^{2, 16}, demonstrating the susceptibility of buffaloes to monensin. In our study, the key to confirm the diagnosis was to measure the monensin level in feed samples. In Argentina, reported outbreaks occurred in cattle^{4, 17} and buffaloes³ in Buenos Aires. However, the concentration of monensin in food was not determined.

An important proportion (17%) of the animals showed muscular weakness due to extensive muscle damage. Clinically, all the signs described agree with the reported natural and experimental cases of ru-

minant intoxicated by monensin^{3, 8, 18-21}. Elevation of serum CPK and AST activities indicated progressive structural muscle damage in affected buffaloes. The elevation of these enzymes in serum has been reported in accidental intoxications with monensin and other ionophore compounds^{1, 8, 9, 13, 19, 21}.

Histopathological studies of the myocardium and skeletal muscle revealed severe degeneration and necrosis. These lesions can explain the disorders in animal attitude and locomotor disorders of affected animals. These lesions were described in sheep^{11, 12}, goat⁸, buffalo³ and cattle poisoned with monensin¹⁹.

In conclusion, this study reaffirms the poisoning by monensin in buffaloes in Argentina, based on clinical signs, enzymogram, pathological lesions and monensin levels in the food. Although the positive effect of monensin has been generally reported as a good additive in food for the performance of the animals, the use of monensin for feeding buffaloes should be made with great caution.

Acknowledgements. We thank Hernán Gomez Danuzzo and José Luis Konrad for his contribution to field work during outbreaks.

REFERENCES

1. **Ashrafihelan J et al.** 2014. High mortality due to accidental salinomycin intoxication in sheep. *Interdiscip Toxicol* 7: 173-176.
2. **Basaraba RJ, Oehme FW, Vorhies MW, Stokka GL.** 1999. Toxicosis in cattle from concurrent feeding of monensin and dried distiller's grains contaminated with macrolide antibiotics. *J Vet Diagn Invest* 11: 79-86.
3. **Bence AR, García J, Fernández E, Morrell E, Cantón, G.** 2018. Hallazgos clínico-patológicos compatibles con intoxicación con ionóforos en búfalos: primer reporte en Argentina. *Rev Vet* 29: 79-82.
4. **Bernerri MJ, Miranda AO, Frances O, Mastrantonio GE.** 2016. Detección espectrofotométrica de sobredosis de monensina en piensos para bovinos. *Rev Vet* 27: 32-35.
5. **Bezerra P, Driemeier D, Loretti A, Riet CF, Kamphues J.** 1999. Monensin poisoning in Brazilian horses. *Vet Hum Toxicol* 41: 383-385.
6. **Bretschneider G.** 2009. Beneficios del uso de monensina en la alimentación del ganado para carne, leche y cría. *Rev Electr Vet* 10.
7. **Chapman H, Jeffers T, Williams R.** 2010. Forty years of monensin for the control of coccidiosis in poultry. *Poult Sci* 89: 1788-1801.
8. **Deljou M et al.** 2014. Clinical, laboratory and pathological findings in sub-acute monensin intoxication in goats. *Vet Res Forum* 5: 161-167.
9. **Dorne J et al.** 2013. Risk assessment of coccidostatics during feed cross-contamination: animal and human health aspects. *Toxicol Appl Pharmacol* 270: 196-208.
10. **Duffield TF, Merrill JK, Bagg RN.** 2012. Meta-analysis of the effects of monensin in beef cattle on feed efficiency,

body weight gain, and dry matter intake. *J Anim Sci* 90: 4583-4592.

11. **Jones A.** 2001. Monensin toxicosis in 2 sheep flocks. *Can Vet J* 42: 135.
12. **Mendes O, Mohamed F, Gull T, C.Bermejillo AD.** 2003. Monensin poisoning in a sheep flock. *Sheep Goat Res J* 18: 109-113.
13. **Miranda A, Harry HA, Francés O, Laudecina VS, Ge- lid L.** 2017. Evaluación de injuria cardíaca en novillos a distintas dosis de monensina sódica dietaria medida a través de creatina kinasa miocárdica. *Ciencia Vet* 18: 59-66.
14. **Nogueira VA, França TN, Peixoto PV.** 2009. Ionophore poisoning in animals. *Pesq Vet Bras* 29: 191-197.
15. **Peek SF et al.** 2004. Atypical acute monensin toxicosis and delayed cardiomyopathy in Belgian draft horses. *J Vet Intern Med* 18: 761-764.
16. **Potter E, Vanduyt R, Cooley C.** 1984. Monensin toxicity in cattle. *J Anim Sci* 58: 1499-1511.
17. **Rodríguez AR et al.** 2004. Posible intoxicación accidental con monensina en terneros destetados. *Vet Arg* 201: 13-20.
18. **Roza DB et al.** 2006. Monensin toxicosis in water buffaloes (*Bubalus bubalis*). *J Vet Diagn Invest* 18: 494-496.
19. **Roza D et al.** 2007. Intoxicação experimental por monensina em búfalos e bovinos. *Pesqui Vet Bras* 27: 172-178.
20. **Schweitzer D, Kimberling C, Spraker T, Stemer F, McChesney AE.** 1984. Accidental monensin sodium intoxication of feedlot cattle. *J Am Vet Med Assoc* 184: 1273-1276.
21. **Silva LF et al.** Clinical and pathological changes in sheep during a monensin toxicity outbreak in Brasilia, Brazil. *Asian J Anim Vet Adv* 11: 73-78.



Revista Veterinaria mantiene su índice de impacto

Noticias de Scimago Research Group (Scimago Journals & Country Ranks, Scopus-Elsevier) comunican que la publicación de nuestra casa, Revista Veterinaria, aumentó su índice de impacto. El índice SJR mide la influencia científica (impacto) del artículo de una revista, expresando cuán importante es el “artículo promedio” de la publicación en la discusión científica global (sistema Thomson Reuters).

Para nuestra revista, tal indicador había sido de 0,03 entre 2008 y 2011, aumentando a 0,05 en 2012, a 0,11 en 2013, a 0,108 en 2015, a 0,100 en 2017 y a 0,114 (Research Gate) en 2018, último período evaluado. Asimismo, surge para nuestra publicación un sostenido descenso del indicador que relaciona “citas versus autocitas”, demostrando que los autores de los artículos están abandonando la práctica de citar sus propias publicaciones anteriores.

Por último, se advierte que según este portal, nuestra “Revista Veterinaria” continúa siendo la única publicación de esta rama de la ciencia que posee índice de impacto en Argentina. Para el resto del cono sur tal distinción recae en Brasil, Chile, Colombia y Venezuela. En revistas de veterinaria, a nivel mundial el mayor índice de impacto (2,911 puntos) recae en Annual Review of Animal Biosciences (Estados Unidos).

Fuente:

<http://www.scimagojr.com/journalrank.php?area>

Retrieved September, 2019.