

UNUSUAL GROSS PRESENTATION OF SARCOCYSTIS-LIKE PECTORAL MUSCLE LYMPHOMA ATTRIBUTED TO MAREK'S DISEASE IN A BACKYARD CHICKEN

Carlos Daniel Gornatti Churria, Med Vet, Panayiotis Loukopoulos, DVM, PG Dip.V St, PhD, Javier Origlia, Med Vet, Nancy Arias, Med Vet, Miguel Herrero Loyola, Med Vet, and Miguel Piscopo, Med Vet

Abstract

Marek's disease-induced lymphomas of skeletal muscle are rarely reported in chickens. Three mixed-breed, adult backyard chickens, which belonged to a flock with a previous history of anorexia, depression, ruffled feathers, whitish diarrhea, weight loss and death, were submitted for *postmortem* examination and diagnostic testing. Grossly, 2 birds had moderate pectoral atrophy, whereas the remaining chicken had numerous white, rice-grain sized foci distributed throughout the pectoral musculature. Severe proventricular wall thickening was observed in all 3 chickens and moderate intestinal *Ascaridia* spp. parasitism was diagnosed in 2 of the birds. Microscopically, the peripheral nerves, cerebrum, proventriculus, and pectoral musculature were severely infiltrated by mononuclear pleomorphic cells. Formalin-fixed, paraffin-embedded tissues from all 3 chickens were polymerase chain reaction positive for Marek's disease virus. A diagnosis of Marek's disease was based on the combined necropsy, histopathology, and polymerase chain reaction findings. This article describes the unusual gross presentation of rice-grain sized and shaped lymphomas in the pectoral musculature of chickens caused by Marek's disease. Copyright 2017 Elsevier Inc. All rights reserved.

Key words: backyard chicken; lymphoma; Marek's disease; *Sarcocystis*-like lesions; pectoral musculature

Marek's disease (MD) is a common lymphoproliferative disease of chickens,^{1,2} which in the absence of preventive measures (e.g., vaccination) can cause high mortality and economic losses in both commercial² and backyard flocks.^{3,4} MD is caused by Gallid herpesvirus 2 (serotype 1), a member of the *Mardivirus* genus and *Alphaherpesvirinae* subfamily.⁵ Based on virulence, Marek's disease virus (MDV) is divided into 4 pathotypes: mild, virulent, very virulent, and very virulent plus strains.^{1,2,6} Often chickens infected with MDV develop characteristic peripheral nerve and visceral lymphomas that may affect a wide range of organs including the gonads, lung, heart, kidney, mesentery, liver, spleen, bursa of Fabricius, thymus, adrenal gland, pancreas, proventriculus, intestine, eye, skeletal muscle, and skin.¹ There is a paucity of information regarding skeletal muscle lymphomas associated with MDV infection in chickens, and all have described variably sized, whitish nodular lesions in the pectoral muscle of pure-breed chickens.⁷⁻⁹ This report describes pectoral muscle lymphomas caused by MDV, grossly mimicking *Sarcocystis*-like rice-grain sized skeletal muscle lesions in chickens.

From the *Cátedra de Patología de Aves y Pilíferos y Laboratorio de Diagnóstico de Enfermedades de las Aves y los Pilíferos, Facultad de Ciencias Veterinarias, Universidad Nacional de La Plata, La Plata, Provincia de Buenos Aires, Argentina; the Veterinary Diagnostic Laboratory, School of Animal and Veterinary Sciences, Charles Sturt University, Wagga Wagga, New South Wales, Australia; and the Graham Centre for Agricultural Innovation, Charles Sturt University, Wagga Wagga, New South Wales, Australia.*

Address correspondence to: Carlos Daniel Gornatti Churria, Med Vet, *Cátedra de Patología de Aves y Pilíferos y Laboratorio de Diagnóstico de Enfermedades de las Aves y los Pilíferos, Facultad de Ciencias Veterinarias, Universidad Nacional de La Plata, 60 y 118 s/n, CC 296, B1900AVW La Plata, Provincia de Buenos Aires, Argentina. E-mail: danielgornatti@fvc.unlp.edu.ar, danielgornatti@gmail.com*

© 2017 Elsevier Inc. All rights reserved.

1557-5063/17/2101-\$30.00

<http://dx.doi.org/10.1053/j.jepm.2016.10.007>

CASE REPORT

Three mixed-breed, adult backyard chickens (chickens 1, 2, and 3) from an MDV unvaccinated flock composed of 100 pure-breed and mixed-breed chickens of different ages were submitted to the Laboratorio de Diagnóstico de Enfermedades de las Aves y los Pilíferos (Cátedra de Patología de Aves y Pilíferos, Facultad de Ciencias Veterinarias, Universidad Nacional de La Plata) in June 2014 for *postmortem* examinations and diagnostic testing. Most of the affected juvenile and adult chickens of the backyard flock had exhibited anorexia, depression, ruffled feathers, whitish diarrhea, and cachexia; 46 chickens (~46%) died. No neurological signs were observed in the affected chickens and none had received therapeutic treatment.

When necropsied, moderate pectoral atrophy was noted in chickens 1 and 2, whereas chicken 3 had numerous well-demarcated, white, rice-grain sized and shaped foci distributed both on the surface and within the pectoral muscle (Figs. 1 and 2). The proventriculus was severely transmurally and circumferentially thickened, obliterating the lumen in all the 3 chickens. Moderate roundworm intestinal parasitism due to *Ascaridia* spp. was identified in chickens 1 and 3.

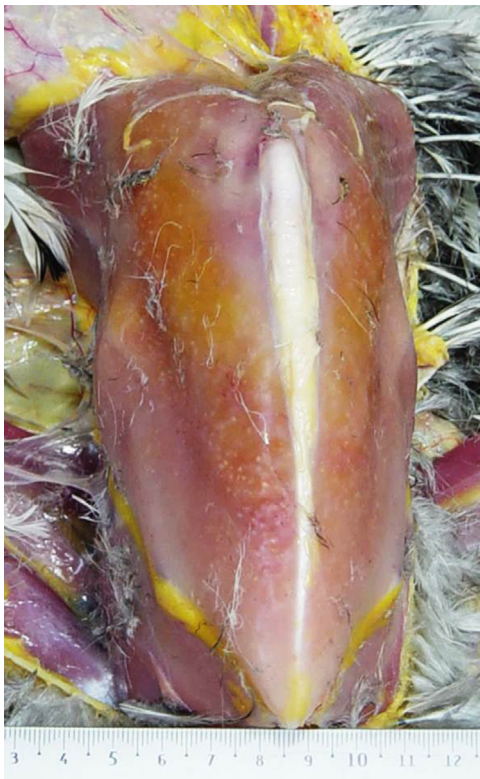

FIGURE 1. Mixed-breed, adult backyard chicken (chicken 3). Note numerous well-demarcated, white, rice-grain sized and shaped areas (lymphoma) on the surface of the pectoral muscle.

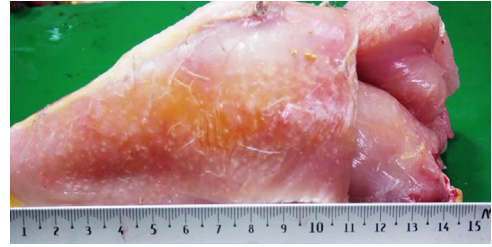


FIGURE 2. Mixed-breed, adult backyard chicken (chicken 3). Note numerous well-demarcated, white, rice-grain sized and shaped areas (lymphoma) on the surface of the pectoral muscle.

Samples of the brain, cervical vagus and sciatic peripheral nerves, lungs, heart, pectoral muscle, liver, spleen, kidneys, proventriculus, ventriculus, gonads, pancreas, and small and large intestine from all 3 chickens were fixed in 10% buffered formalin, pH 7.2, for 48 hours. All tissues were processed by standard histological techniques for the production of 4- μ m thick hematoxylin and eosin stained sections. Fresh samples of the liver and spleen of the 3 birds were inoculated onto MacConkey agar (Oxoid Ltd., Hampshire, UK) and sheep blood agar (Oxoid Ltd.) plates and incubated aerobically at 37°C for 24 hours. DNA was extracted from formalin-fixed, paraffin-embedded (FFPE) tissues of all birds by the use of a DNA commercial extraction kit (QIAamp DNA FFPE Tissue Kit, QIAGEN, GmbH, Hamburg, Germany) according to the manufacturer's instructions. Amplification and detection were carried out with an IQ5 Multicolor Real-Time PCR Detection System (Bio-Rad Laboratories, CA USA) by using SYBR Green (SYBR Green PCR Master Mix, Applied Biosystems, Life Technologies, CA USA) chemistry to detect the *meq* gene of the virus as described by Abdul-Careem et al.¹⁰ Intestinal contents of the 3 chickens were pooled and analyzed by a fecal floatation test.

RESULTS AND DISCUSSION

Microscopically, the pectoral musculature of chicken 3 showed multifocal to coalescing pleomorphic mononuclear cell infiltration (PMCI), which was prominent in several perivascular, primarily periarterial areas (Fig. 3). The PMCI is composed of variably sized large, neoplastic lymphocytes, including large blastic lymphocytes together with a small number of macrophages (Fig. 4). The infiltrating neoplastic lymphocytes were characterized by distinct cellular borders and rounded nuclei with dense chromatin surrounded by scarce cytoplasm (Fig. 4), and a low to moderate degree of necrosis and mitotic index.

Multifocally, myofibers adjacent to the areas showing PMCI were separated in bundles, and showed degeneration and coagulative necrosis. Similar neoplastic cell infiltration was observed in all 3 chickens in the cerebrum, with mild-to-moderate PMCI cuffing and multifocal gliosis; the cervical vagus and sciatic nerves with severe, diffuse, PMCI, no edema and diffuse demyelination with digestive chambers; and the proventriculus with severe, multifocal to coalescing, submucosal PMCI.

Histopathologically, no noteworthy changes were found in the cerebellum, heart, lungs, liver, spleen, kidneys, gonads, ventriculus, pancreas, and small and large intestine in any of the chickens examined.

No bacterial growth was observed in either MacConkey or sheep blood agar plates. Other than the *Ascaridia* spp. diagnosed in chickens 1 and 3, no evidence of parasites was found in the pooled intestinal content of the 3 birds.

Real-time polymerase chain reaction of all FFPE tissues harvested were positive against MDV in the cerebrum, cervical vagus and sciatic nerves, and proventriculus of all the 3 birds and in the pectoral muscle of chicken 3.

Sarcocystosis is caused by apicomplexan protozoal parasites of the genus *Sarcocystis* and is occasionally reported in poultry.¹¹ The *Sarcocystis* spp. parasite can cause severe debilitation and death in wild turkeys and backyard chickens.¹¹ The parasitic disease is recognized by the presence of elongated cysts (sarcocysts) (i.e., noted grossly as rice-grain sized lesions) located in skeletal musculature of the breast, thigh, and neck of birds.¹¹ Although MD is recognized as one of the major disease threats for chickens and represents one of the leading causes of mortality in backyard

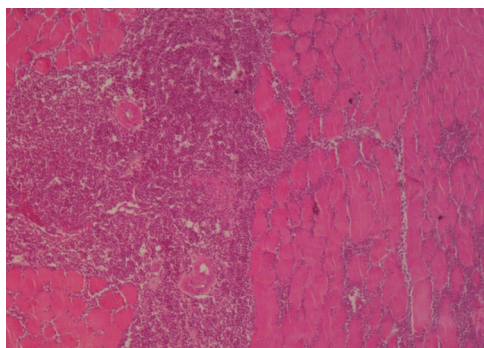


FIGURE 3. Mixed-breed, adult backyard chicken (chicken 3). Note multifocal to coalescing pleomorphic mononuclear cell infiltration in the pectoral muscle separating bundles and prominent in perivascular, primarily periarterial areas (Hematoxylin and eosin).

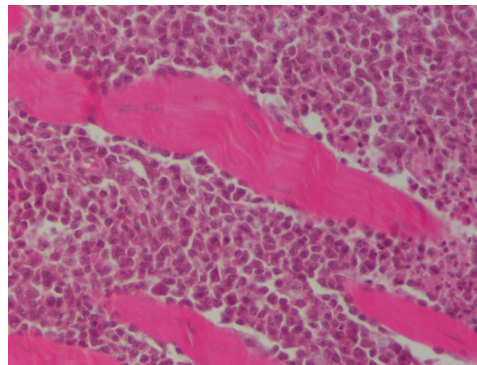


FIGURE 4. Mixed-breed, adult backyard chicken (chicken 3). Note the pleomorphic mononuclear cell infiltration composed of variably sized lymphocytes and macrophages. Skeletal muscle degenerative and necrotic changes are also noted (Hematoxylin and eosin).

flocks,^{3,4} there are only a few reported cases of pectoral muscle lymphomas due to MDV infection in this avian species. In this case, the gross, histopathological, and polymerase chain reaction results provided the definitive diagnosis of MD in the 3 chickens submitted for examination. MDV lymphoma grossly mimicked *Sarcocystis* spp. infection in the skeletal muscles of chicken 3.¹¹ With the unusual presentation described in this report, one should consider adding MD to the differential disease diagnosis list when skeletal muscle lesions in chickens from backyard flocks resemble those of sarcocystosis.

REFERENCES

1. Shat K, Nair V: Marek's disease, in Swayne D, Glisson JR, McDougald LR (eds): *Diseases of Poultry*. (ed 13). Ames, IA, Wiley-Blackwell, pp 515-552, 2013
2. Gimeno IM: Marek's disease vaccines: A solution for today but a worry for tomorrow? *Vaccine* 26S:C31-C41, 2008
3. Mete A, Giannitti F, Barr B, et al: Causes of mortality in backyard chickens in Northern California: 2007–2011. *Avian Dis* 57:311-315, 2013
4. Crespo R, Senties-Cue G: *Post mortem* survey of disease conditions in backyard chickens. *J Exot Pet Med* 24: 156-163, 2015
5. Carvallo FR, French RA, Gilbert-Marcheterre K, et al: Mortality of one-week-old chickens during naturally occurring Marek's disease virus infection. *Vet Pathol* 48: 993-998, 2011
6. Greenacre CB: Musculoskeletal diseases, in Greenacre CB, Morishita TY (eds): *Backyard Poultry Medicine and Surgery: A Guide for Veterinary Practitioners*. Ames, IA, Wiley-Blackwell, pp 145-159, 2015
7. Fujimoto Y, Nakagawa M, Okada K, et al: Pathological studies of Marek's disease: I. The histopathology on field cases in Japan. *Jpn J Vet Res* 19:7-26, 1971
8. Simpson CF: Herpesvirus-like particles in tumor cells of breast muscle of chickens with Marek's disease. *Avian Dis* 21:402-407, 1977

-
9. Deshmukh S, Banga HS, Singh ND, et al: Histopathological characterization of Marek's disease virus induced breast muscle lymphoma in a Rhode Island Red fowl. *Anim Sci Rep* 6:43-46, 2012
 10. Abdul-Careem MF, Hunter BD, Nagy E, et al: Development of a real-time PCR assay using SYBR Green chemistry for monitoring Marek's disease virus genome load in feather tips. *J Virol Methods* 133: 34-40, 2006
 11. Bermudez AJ: Miscellaneous and sporadic protozoal infections, in Swayne D, Glisson JR, McDougald LR (eds): *Diseases of Poultry*. (ed 13). Ames, IA, Wiley-Blackwell, pp 1182-1194, 2013