

Carnivores as zoonotic parasite reservoirs in ancient times: the case of the Epullán Chica archaeological cave (Late Holocene, northwestern Patagonia, Argentina)

María Ornela Beltrame^{1,2} · Agustín Bellusci¹ · Fernando Julián Fernández^{2,3} · Norma Haydée Sardella^{1,2}

Received: 15 April 2016 / Accepted: 26 September 2016 / Published online: 7 October 2016
© Springer-Verlag Berlin Heidelberg 2016

Abstract Zoonoses are currently considered as one of the most important threats for Public Health worldwide. Numerous zoonoses known today have occurred since antiquity. Carnivores act as definitive hosts for many intestinal parasites; some of them are responsible for several zoonotic diseases. The aim of this work was to study the parasite remains found in coprolites assigned to carnivores from the archaeological site Epullán Chica (ECh) and to discuss the results from a zoonotic point of view. ECh is located in northwestern Patagonia, Argentina and was occupied since the end of the Late Holocene (~2200 years B.P.). Nine coprolites were examined for parasites. Samples were processed by rehydration in a 0.5 % water solution of trissodium phosphate, followed by homogenization, filtered and processed by spontaneous sedimentation. The macroscopic remains were separated and dried at room temperature and were examined for diet analysis. Six out of 9 coprolites examined were positive for parasites. Representatives of at least 10 parasite taxa were registered. Results are in line with the reconstruction of the scenario of zoonoses in the past and the diseases that the human populations and animals from Patagonia could be exposed. The present study provides the first palaeoparasitological

report of carnivore coprolites recovered from the archaeological site ECh and reflects contamination of the cave used by hunter-gatherers with different parasites causative of zoonotic diseases.

Keywords Palaeoparasitology · Patagonia · Carnivores · Zoonoses

Introduction

Zoonoses are defined as any disease or infection that is naturally transmissible from vertebrate or invertebrate animals to humans and vice versa. Zoonoses are currently considered as one of the most important threats for Public Health worldwide. Viruses, parasites, bacteria and fungi can cause zoonotic infections (Bueno-Marí et al. 2015). Numerous zoonoses known today have occurred since antiquity.

Palaeoparasitology is the study of parasite remains from archaeological and palaeontological sites (Ferreira 2014), focussed on the knowledge of parasite-induced illness of humans in the past and on the palaeoecological knowledge of the environment, ecology, settlement, diet, hygiene and health in the antiquity (Reinhard 1992). Previous palaeoparasitological studies on South American ancient populations have shown the presence of the zoonotic helminths *Echinostoma* sp., *Paragonimus* sp., *Diphyllobothrium* spp., *Capillaria* spp., *Trichostrongylus* sp. and Acanthocephala (Sianto et al. 2009).

Carnivores act as definitive hosts for many intestinal parasites; some of them are responsible for several zoonotic diseases such as paragonimiasis, sarcocystosis, toxoplasmosis and cysticercosis (Jay 1996, Acha and Szyfres 2003). Current diversity of South American terrestrial carnivores is relatively high, with 40 out of 245 species of the order

✉ María Ornela Beltrame
omelabeltrame@conicet.gov.ar

¹ Laboratorio de Paleoparasitología y Arqueología Contextual, Departamento de Biología, Facultad de Ciencias Exactas y Naturales, Universidad Nacional de Mar del Plata, Funes 3250, 7600 Mar del Plata, Buenos Aires, Argentina

² Consejo Nacional de Investigaciones Científicas y Técnicas (CONICET), Buenos Aires, Argentina

³ Cátedra de Anatomía Comparada, Facultad de Ciencias Naturales y Museo, Universidad Nacional de La Plata, calle 64 s/n (entre diag. 113 y calle 120), 1900 La Plata, Buenos Aires, Argentina

Carnivora (Hunter 2011). The palaeontological record exhibits that a rich diversity of carnivores also inhabited South America in the past (e.g. Soibelzon and Prevosti 2007).

From ancient times, a close interaction between humans and carnivores was present. This interaction may have favoured the transmission of zoonotic parasitic diseases. The study of carnivore parasites can improve the knowledge of human zoonotic parasitic diseases in the past.

The archaeological site Epullán Grande cave is located in the middle Limay River basin (northwestern Patagonia, Argentina) and yielded remains from ca. 10,000 years B.P. (before present) (Crivelli Montero et al. 1996). About 100 m east from this cave is located a smaller archaeological cave site, Epullán Chica (ECh), with a rich zooarchaeological record, occupied since the end of the Late Holocene (Fernández et al. 2016). The zooarchaeological material present in both caves evidences the interaction between hunter-gatherers and animals from Pleistocene-Holocene transition to historical times.

The aim of this work was to study the parasite remains found in coprolites assigned to carnivores from the archaeological site Epullán Chica and to discuss the results from a zoonotic point of view.

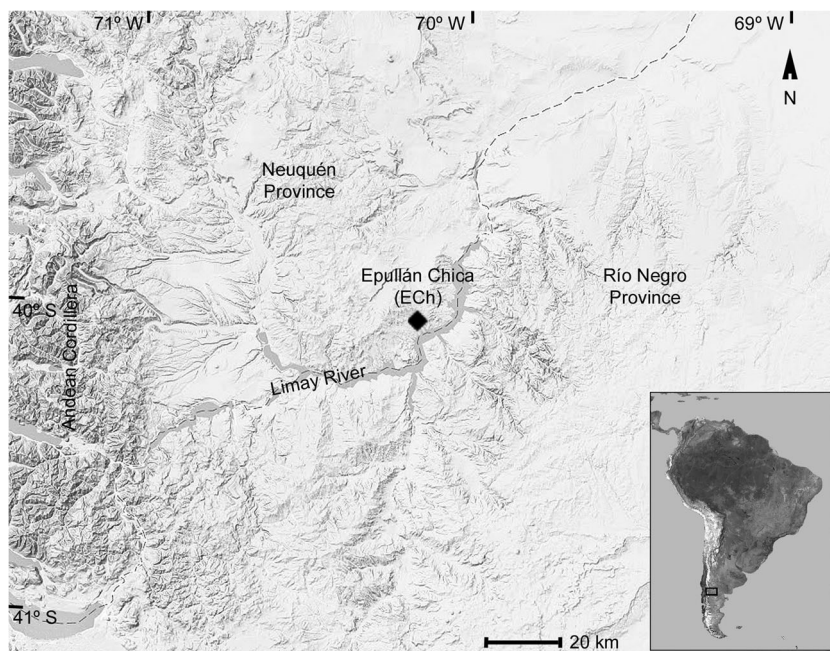
Material and methods

The archaeological site named Epullán Chica (ECh) is a cave located at the southern of Neuquén Province, Argentina, 5 km north of the Limay river valley (40° 23' 10" S, 70° 11' 44" W, 680 m) (Fig. 1). It is 5 m wide at the mouth and 3.5 m long and covers 11 m². Maximum depth of the fill was 1.40 m. The

archaeological sequence was dated around 2220 ± 50 years ¹⁴C B.P. (from a charcoal sample recovered from the deeper layers) to the twentieth century (from a metal knife collected from the upper layers). ECh is located in the Monte-Patagonia ecotone of the three major vegetation units that occur in Patagonia: forest, Patagonian steppe and Monte desert. The annual precipitation is around 300 mm. Archaeological materials were recovered, including lithic artefacts, plant remains, owl pellets, freshwater mollusc shells (*Diplodon chilensis*), feathers of *Cyanoliseus patagonus* (burrowing parakeet), bones and egg shell fragments of Rheidae birds (*Rhea americana* [greater rhea] and *R. pennata* [lesser rhea]) and bones and teeth from large, medium and small-sized mammals, such as *Lama guanicoe* (guanaco), *Chaetophractus villosus* (large hairy armadillo), *Leopardus geoffroyi* (Geoffroy's cat), *Lycalopex griseus* (grey fox or chilla), *Galictis cuja* (lesser grison), *Conepatus chinga* (Molina's hog-nosed skunk), *Microcavia australis* (southern mountain cavy) and numerous sigmodontine rodents (Fernández et al. 2016).

Nine coprolites collected from unit II from ECh (1980 ± 80 to 1740 ± 60 years ¹⁴C B.P.) were examined for parasites. The coprolites were described, measured and weighted. The smaller samples were whole processed by rehydration in a 0.5 % water solution of trissodium phosphate (TSP) in a glass tube for at least 72 h, followed by homogenization, filtered and processed by spontaneous sedimentation (Lutz 1919). In the case of bigger samples, 0.5 g from the surface and the interior of coprolites was rehydrated. Samples were preserved in 70 % ethanol. Twenty slides of each sample were made with the aid of a drop of sediment mixed with one drop of glycerin and examined at 100× and 400× using a light microscopy. The

Fig. 1 Map of the archaeological site Epullán Chica cave, northwestern Patagonia, Argentina



measurements are based on those taken from well-preserved eggs. Egg dimensions and morphologies were compared with data from the literature in order to identify the parasites at the lowest taxonomic level. The macroscopic remains were separated and dried at room temperature and were examined for diet analysis.

Results

Table 1 presents measurements, microscopic and macroscopic remains and parasitological records of each coprolite. Macroscopic remains found in coprolites were indicative of an omnivorous diet. Coprolites number 1, 2 and 3 showed a mixture of inclusions such as small bone fragments, diminutive vertebrae and ribs, scales of reptiles, vegetal remains and chitin of insects. Coprolites showed dark colouration; they were very light and easily broken. Coprolites 4 to 9 were brown and cylindrical. Macroscopic observation of coprolite 4 displays light brown hairs, vegetal remains and fragments of insect exoskeletons. Coprolites 5 to 9 showed vegetal and insect remains. Coprolite 7 also displays diatoms. After rehydration, all samples exhibited a dark colouration (typical of carnivore faecal material) and the coprolite number 3 presented an intense smell.

Microscopic observations revealed that 6 coprolites examined contained parasite remains. At least representatives of 10 species of helminths were recovered. Helminth eggs of

nematodes, cestodes and acanthocephalans were found (Table 1). In all cases, eggs were very well-preserved.

Two different nematodes were found in coprolite number 1 (internal and external samples). In one case, eggs were oval, smooth, thick-shelled and embryonated. Their measurements were 45.0 to 55.0 μm ($48.69 \pm 2.50.32$; $N = 22$) in length and 32.5 to 37.5 μm (34.83 ± 1.71 ; $N = 20$) in width. The identity of eggs was attributed to genus *Physaloptera* sp. (Molin 1860) (Spirurida: Physalopteridae) (Fig. 2). The other eggs were oblong and thin-shelled and were observed both as embryonated or unembryonated. Egg measurements ($N = 3$) were 85.0 to 90.0 μm (87.48 ± 2.5) in length and 47.5 to 50.0 μm (49.15 ± 1.44) in width. These eggs were attributed to ancylostomids, probably *Uncinaria* sp. (Froelich 1789) (Strongylida, Ancylostomatidae) (Fig. 3).

Three different parasite species were found in pellet number 2. Eggs identified as acanthocephalan (Archiacanthocephala, Oligacanthorhynchidae), probably *Prostenorchis* sp. (Travassos 1915), were brown-coloured and thick-shelled, with four membranes. The outer membrane was thick, granular and with hyaline poles; the inner membrane thin and the embryos with hooks in one extremity (Fig. 4). Eggs were found in internal and external samples. Egg measurements ($N = 18$) ranged from 90.0 to 100.0 μm (96.20 ± 3.16) long and 47.5 to 57.5 μm (50.38 ± 3.06) wide; they were found from both internal and external samples.

Eggs comparable to a trematode were also found (internal sample). Eggs were ovoid, brownish yellow, thick-shelled,

Table 1 Measurements, microscopic and macroscopic remains and parasitological records of each coprolite

Coprolite no.	Diameter (mm)	Macroscopic and microscopic remains	Parasite eggs
1	10.15	Bones (ribs, vertebrae), reptile scales, arthropod chitin	<i>Physaloptera</i> sp. <i>Uncinaria</i> sp.
2	12.89	Bones fragments, arthropod chitin, vegetal tissues, reptile scales	<i>Prostenorchis</i> sp. <i>Paragonimus</i> sp. <i>Ancylostoma</i> , probably <i>A. conepati</i>
3	16.92	Arthropod chitin, vegetal tissues, pollen grains,	<i>Eucoleus</i> , probably <i>E. aerophilus</i>
4	15.48	Arthropod chitin, vegetal tissues, pollen grains	Negative
5	18.51	Arthropod chitin, vegetal tissues, pollen grains	<i>Trichostrongylus</i> , probably <i>T. colubriformis</i> <i>Physaloptera</i> sp. Ascarididae
6	14.14	Arthropod chitin, vegetal tissues, pollen grains	<i>Monoecocestus</i> sp. <i>Physaloptera</i> sp.
7	12.51	Arthropod chitin, vegetal tissues, diatoms, pollen grains	Negative
8	16.92	Arthropod chitin, vegetal tissues, pollen grains	Ascarididae
9	14.16	Arthropod chitin, vegetal tissues, pollen grains	Negative

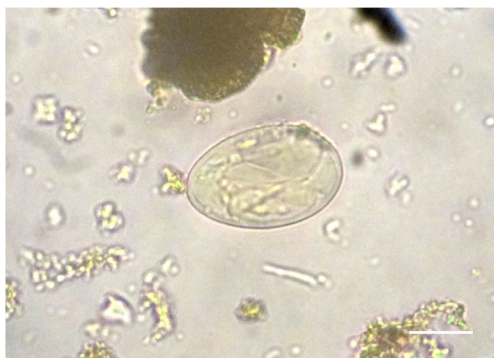

Fig. 2 Eggs found from Epullán Chica cave, tentatively attributed to genus *Physaloptera* sp. (Spirurida: Physalopteridae). Bar = 20 μ m

unembryonated and operculated (Fig. 5). The posterior end was thickened. The average measurements of eggs were 80.82 ± 1.44 by 56.33 ± 7.64 μ m ($N = 3$). Eggs were attributed to genus *Paragonimus* (Platyhelminthes: Trematoda) (Braun 1899). Two eggs of nematodes attributed to *Ancylostoma* (Strongylida, Ancylostomatidae), probably *A. conepati* (Solonet 1911), were also found in coprolite 2 (internal sample). Eggs were ovoid with a thin shell. Measurements were 75 by 42.5 μ m (Fig. 6).

One egg compatible with the capillariid *Eucoleus* sp. (Nematoda: Capillariidae) (Fig. 7), probably *E. aerophilus*, was found in coprolite number 3 (internal sample). The surface of the wall exhibited a network of ridges. Egg measurements were 50.0 (without plugs) and 62.5 (with plugs) in length and 27.5 in width respectively.

Coprolite number 5 harboured 5 nematode species. Oblong, thick-shelled and embryonated eggs similar to that of spirurid species were observed. Egg measurements ($N = 11$) were 62.5 to 67.5 μ m (62.19 ± 3.25) in length and 42.5 to 57.5 μ m (46.17 ± 4.52) in width. Eggs were probably attributed to *Physaloptera* sp. (Fig. 8), but to another species to that of coprolite 1.

Oblong and larvated eggs with a thin wall were also found. Measurements ($N = 3$) were 112.5 to 115.0 μ m (113.33 ± 1.44) in length and 50 to 62.5 μ m (57.24 ± 6.61) in width. Eggs were

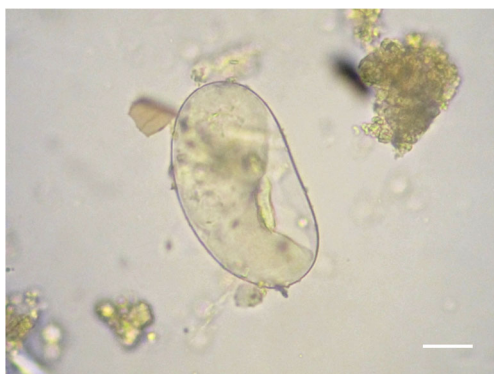

Fig. 3 Eggs found from Epullán Chica cave, attributed to ancylostomids, probably *Uncinaria* sp. (Strongylida, Ancylostomatidae). Bar = 20 μ m

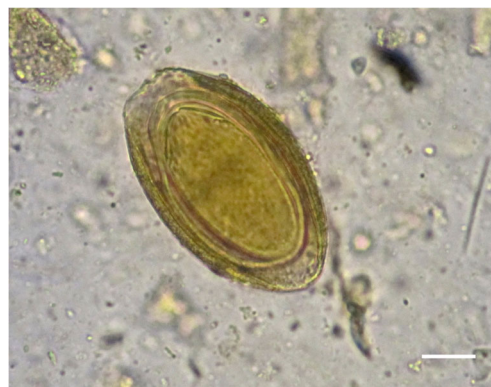

Fig. 4 Eggs found from Epullán Chica cave, identified as acanthocephalan (Archiacanthocephala, Oligacanthorhynchidae), probably *Prostenorchis* sp. Bar = 20 μ m

compatible to strongylid eggs (Strongylida, Trichostrongyloidea) (Fig. 9). Their morphology and measurements were similar to those of *Trichostrongylus*, probably *T. colubriformis*. Hatched larvae were observed.

Three morphotypes of nematode eggs possibly belonged to the family Ascarididae were recorded. Eggs were in different embryonic stages. In none of these cases was the diagnosis possible. In one case, eggs were rounded with mamillated wall and embryonated. The average measurements of eggs were 61.71 ± 7.49 by 47.88 ± 1.88 μ m ($N = 6$) (Fig. 10). The other ascaridid eggs were brown and ellipsoid, unembryonated. The average measurements of eggs were 52.96 ± 2.30 by 37.97 ± 1.58 μ m ($N = 10$) (Fig. 11). Rounded, embryonated, translucent and mamillated eggs were also found. The average measurements of eggs were 54.15 ± 1.44 by 51.57 ± 3.82 μ m ($N = 3$) (Fig. 12).

Coprolite number 6 displayed one egg of anoplocephalid (Cestoda: Anoplocephalidae), with characteristics attributable to genus *Monoecocestus* (Beddard 1893) (Fig. 13). Measurements of the egg were 72.5 by 55 μ m. Nematode eggs, similar to those found in coprolite number 5, attributable to *Physaloptera* sp., were also found. Egg measurements ($N = 6$) were 55.0 to 62.5 μ m (58.27 ± 3.03) in length and 45.0 to 47.5 μ m (46.23 ± 1.37) in width.

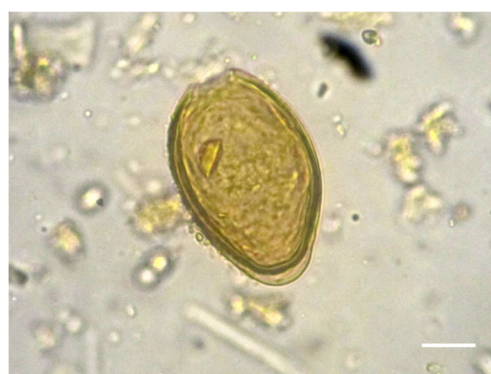

Fig. 5 Eggs found from Epullán Chica cave, attributed to genus *Paragonimus* (Platyhelminthes: Trematoda). Bar = 20 μ m

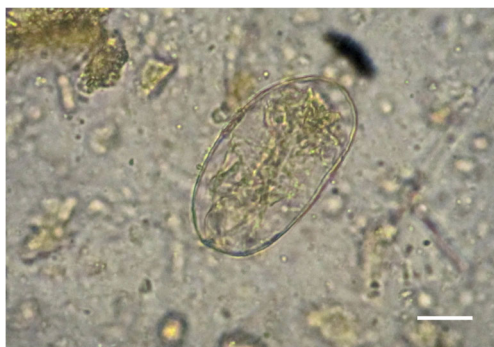

Fig. 6 Eggs found from Epullán Chica cave, attributed to *Ancylostoma* (Strongylida, Ancylostomatidae). Bar = 20 μm

Coprolite 9 contained ascaridid eggs (Nematoda: Ascarididae). Eggs were rounded and embryonated, with mamillated walls and similar to those found in coprolite 5 (Fig. 10). The average measurements of eggs were 60.56 ± 3.42 by 49.15 ± 2.51 μm ($N = 19$).

Discussion

Based on morphological features and diet, coprolites were assigned as belonging to any representative from Order Carnivora. The carnivore species currently living in the studied area are *Lycalopex culpaeus* (culpeo fox) and *L. griseus* (Canidae), *Leopardus colocolo* (pampas cat), *L. geoffroyi*, *Puma concolor* (puma) (Felidae), *C. chinga* (Mephitidae), *G. cuja* and *Lyncodon patagonicus* (Patagonian weasel) (Mustelidae) (Barquez et al. 2006). Several bones of them, including the four aforementioned families, were identified in ECh (see “Material and Methods” section).

The faeces of carnivores are characterized by their cylindrical shape, with subdivisions and tapered at one of the extremities (Chame 2003). However, in *C. chinga*, these subdivisions are not easy to distinguish (Medina et al. 2009). Hog-nosed skunks (*Conepatus*) are carnivores widely distributed, ranging from Texas to the outermost areas of South

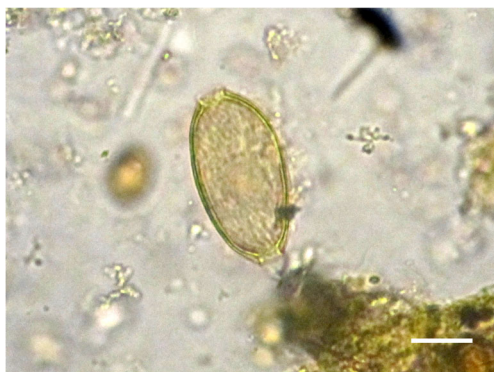

Fig. 7 Egg found from Epullán Chica cave, compatible with the capillariid *Eucoleus* sp. (Nematoda: Capillariidae), probably *E. aerophilus*. Bar = 20 μm

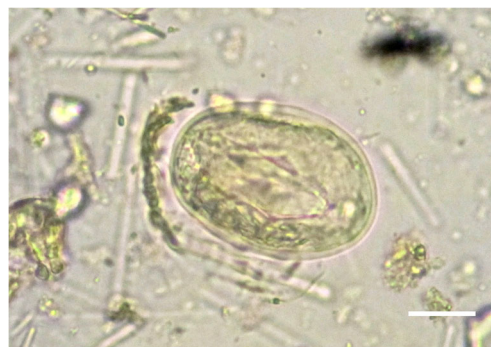

Fig. 8 Eggs found from Epullán Chica cave were probably attributed to *Physaloptera* sp. (Spirurida: Physalopteridae). Bar = 20 μm

America. The skunk *C. chinga* is a mephitid whose distribution ranges from northeastern Perú to southern Chile and to certain areas of Bolivia, Paraguay, Uruguay, Argentina and Brazil. Studies on the feeding habits of *C. chinga* suggest a generalist consumer character, in which arthropods are the most frequent prey, although small mammals are also a substantial part of its diet (Castillo et al. 2014; Donadío et al. 2004; Medina et al. 2009). Other preys include annelids, amphibians, reptiles and carrions. The morphology, diet and measurements of the examined coprolites 1, 2 and 3 were similar to those of *C. chinga*.

Faeces 4 to 9 exhibited the typical carnivore characteristics. Their measures and morphology correspond to those of a small canid or feline. However, the diets of Felidae tend to be more specific than those of other Carnivora, generally consisting of mammalian prey of sizes commensurate with their own body size, with little or no fish, vegetation or invertebrates (Kruuk 1986; Walker et al. 2007). In general, foxes tend to be omnivorous and opportunistic. The grey fox is both diurnal and nocturnal and occurs in a broad range of habitats from grasslands to forests, although in Argentina, it typically inhabits arid and semiarid temperate portions of Patagonia and the Andes. *L. griseus* is a generalist omnivore. The diet may contain plant material, insects, birds, rodents, lizards and even a high amount of fruit (Núñez and Bozzolo 2006; Zapata et al. 2005). Measurements of studied coprolites were similar to that



Fig. 9 Eggs found from Epullán Chica cave, compatible to *Trichostrongylus* sp. (Strongylida, Trichostrongyloidea). Bar = 40 μm

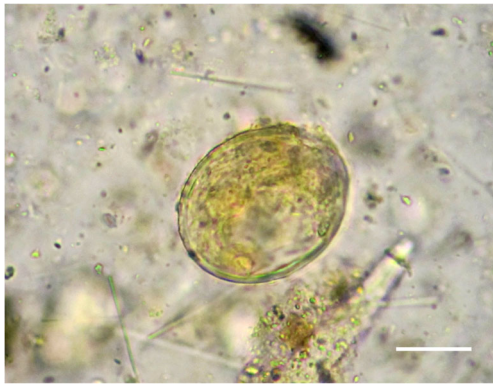

Fig. 10 Eggs found from Epullán Chica cave, belonged to the family Ascarididae. Bar = 20 μ m

of *L. griseus*. *L. culpaeus* has a narrower diet than *L. griseus*, being exclusively carnivorous and their faeces are bigger (Zapata et al. 2005).

Little is known about the parasite fauna of *C. chinga*. *Spirometra erinacei* and *Atriotaenia sanmarci* (cestodes) and *A. conepati*, *Physaloptera cahuide* and *Physaloptera maxillaris* (nematodes) were reported (Gomez-Puerta et al. 2009, 2012; Sarmiento et al. 1999; Stein et al. 1994; Vega et al. 2014; Vieira et al. 2008).

Species of *Physaloptera* are parasitic nematodes with the adult stages living in the digestive tract of amphibians (3 species), reptiles (45 species), birds (24 species) and mammals (over 90 species) and more than 82 cases were described from humans (Mohamadain and Ammar 2012). Their life cycle includes intermediate hosts (orthopterans and coleopterans) or paratenic hosts that harbour larval forms in the outer intestinal wall (Quadros et al. 2014). Domestic and wild carnivores (cougar, lynx, badger, raccoon, fox, striped hog-nosed skunk and coyote) may be infected after eating arthropods containing third-stage larvae. The development into the adult form takes place in the definitive host and the worms lodge, preferably in the oesophagus, in the gastric mucosa and in the small intestine (Ortlepp 1922). Frequent movement of these nematodes results in erosions and ulcers in the gastrointestinal tract (Naem and Asadi 2013). *Physaloptera maxillaris* was the most common helminth reported from striped skunks



Fig. 11 Eggs found from Epullán Chica cave, possibly belonging to the family Ascarididae. Bar = 20 μ m

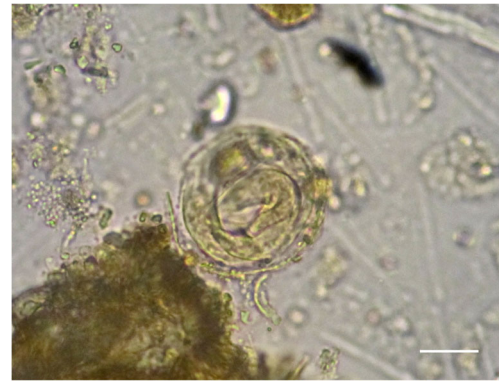

Fig. 12 Eggs found from Epullán Chica cave, belonged to the family Ascarididae. Bar = 20 μ m

(*Mephitis mephitis*) from USA (Dyer 1970; Lincoln and Anderson 1972) and from hog-nosed skunks (*Conepatus leuconotus*), striped skunks (*M. mephitis*) and spotted skunks (*Spilogale gracilis*) from an area of sympatry from Texas (Neiswenter et al. 2006). Humans on rare occasions have been infected with this parasite. *Physaloptera* was identified in other prehistoric coprolites, which belonged to a canid (Fugassa et al. 2006), to a prehistoric human from Patagonia, Argentina (Fugassa et al. 2007) and to a human from the “La Cueva de los Muertos Chiquitos” archaeological site, México (Clelland et al. 2013).

Paragonimus species are extremely successful parasites with more than 40 species described (Blair et al. 2005). *Paragonimus* spp. exhibit a complex life cycle that includes a mammal as the definitive host and snails and crustaceans as intermediate hosts (crabs and crayfish). Definitive hosts usually become infected by eating raw or undercooked tissues from crustaceans. Paragonimiasis is a disease of humans and other mammals caused by several species of *Paragonimus*. Symptoms and signs mimic those of tuberculosis (Diaz 2013; Procop 2009). Human infections are present in Africa, Asia and America, including USA, Mexico, Costa Rica, Guatemala, Honduras, Nicaragua, Panamá, Colombia, Perú, Venezuela and Brazil (Acha and Szyfres 2003). *Paragonimus*

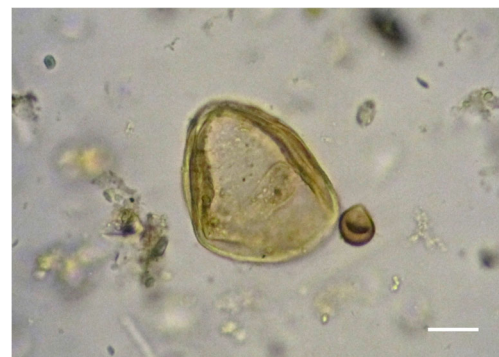

Fig. 13 Anoplocephalid egg (Cestoda: Anoplocephalidae) found from Epullán Chica cave, with characteristics attributable to genus *Monoecocestus*. Bar = 20 μ m

has not been reported from Argentina. There is only one previous palaeoparasitological record by Hall (1976) (in Horne 1985), who reported eggs of *Paragonimus*, from human coprolites from the Atacama Desert of northern Chile dated to 5900 B.P. Exoskeletal fragments of freshwater crayfish or shrimp were found in the same coprolites. Eggs were found in a coprolite probably assigned to the skunk. Presidente and Ramsden (1975) found *P. kellicotti* infection in striped skunks (*M. mephitis*) and also in minks (*Mustela vison*), red foxes (*Vulpes vulpes*) and coyotes (*Canis latrans*).

Individuals belong to the phylum Acanthocephala are exclusively parasitic, including approximately 1150 described species with indirect life cycles, always involving arthropods as intermediate hosts and vertebrates as definitive hosts (Kennedy 2006). A main characteristic of the phylum is a protrusible proboscis armed with recurved hooks. Worms are attached to the intestine walls of the definitive host. The family Oligacanthorhynchidae includes 12 genera (Amin 2013). One of them, *Prosthenorchis*, has been reported from South America, as *P. elegans* from primates and *P. cerdocyonis* from the crab-eating fox *Cerdocyon thous*; from Africa, as *P. lemuri* from lemurs in Madagascar, *P. pardalis* from *Felis pardus* in Sierra Leone and *P. fraterna* from felid *Panthera pardus* in Congo; and from Asia as *P. sinicus*, from a dog in China (Amin 2013; Gomes et al. 2015). Eggs identified as *Macracanthorhynchus* sp. or an unidentified species were found in raptor pellets from the same layer of ECh (Beltrame et al. 2015). There is scarce information of Oligacanthorhynchids from South America. Although very rare, acanthocephalan human infection does occur. The earliest discovery of infection was from the coprolite of a prehistoric man in Utah with a significant number of *Moniliformis* eggs (Moore et al. 1969). The finds of acanthocephalans from North American archaeological sites were summarized by Fugassa et al. 2011. Most patients with acanthocephalan infection remain asymptomatic, but others experience abdominal pain, diarrhea and anorexia with weight loss (Andres et al. 2014; Salehabodi et al. 2008).

Parasites of the superfamilies Strongyloidea, Trichostrongyloidea and Ancylostomatoidea are nowadays of major importance in human and veterinary medicine. The strongylid species found in carnivores belong to the suborder Strongylida (Ancylostomatidae) (Anderson et al. 2009). The most common species found are *Ancylostoma* spp. and *Uncinaria* spp. The life cycle of these hookworms begins with the larvae hatching from eggs that passed in the host's faeces, developing to the infective stage (filariform larva) in soil and accessing to the definitive host through skin penetration or via ingestion. Infective larvae can also establish infections if ingested. Larvae that penetrate the skin travel through various organs, including the respiratory tract, before entering the intestines and developing into mature hookworms. Hookworms can cause anaemia, abdominal pain and diarrhoea when they reside

in the intestines or lungs with dermatologic and other signs during their migration through the body (Bowman et al. 2010; Traversa et al. 2014). Zoonotic hookworms in humans may cause different pictures of skin, enteric and pulmonary diseases, the cutaneous larva *migrans* being the most important.

From South America, *Ancylostoma* and *Uncinaria* are usually found in several species of domestic carnivorous as dogs and cats, as well as wild carnivorous as Darwin's fox (*Lycalopex fulvipes*) from Chile (Jiménez et al. 2012), *L. griseus* from Argentina (Zanini et al. 2006), *L. geoffroyi* from Argentina (Beldoménico et al. 2005), stray cat (*Felis catus*) from Brazil (Uchôa et al. 1998) and *A. braziliense* and *P. concolor* from Brazil. *U. stenocephala* was found in *L. culpaeus* from Tierra del Fuego, Argentina (Aguilera 2001), from the Magellanic and Arctic regions of Chile (Alarcón Navarro 2005) and from Perú (Moro et al. 1998). *Ancylostoma conepati* was found in *C. chinga* from Perú and Brazil (Sarmiento et al. 1999; Vieira et al. 2008) and from Chubut Province, Argentina (Vega et al. 2014).

Trichostrongylus spp. are primarily parasites of herbivores with a worldwide distribution. Human infections are found mainly in warm areas. *T. colubriformis* adults live in the intestines of the host. The female lays eggs with faeces. Eggs hatch and mature into infectious larvae. Humans become infected, ingesting unwashed vegetables contaminated by animal faeces or contaminated water containing strongyloid larvae. Larvae mature into adults in the intestines. The zoonotic trichostrongylosis is produced by several species of *Trichostrongylus*. Sporadic cases of *T. colubriformis* in humans have been reported (Lattès et al. 2011; Sato et al. 2011). Their presence in carnivores is accidental. *T. colubriformis* was also found in *L. griseus* from Chile (Alarcón Navarro 2005).

Another nematode frequently associated to wildlife is *E. aerophilus* (syn. *Capillaria aerophila*). It is a trichuroid nematode affecting the respiratory system of dogs, cats, wild carnivores and occasionally humans (Traversa et al. 2011). Adult stages live embedded underneath the epithelium of trachea, bronchi and bronchioles of the infected host. Females produce non-larvated eggs, which are coughed up and swallowed, reaching the environment via the faeces, where eggs mature. Eggs may also mature within earthworms (facultative intermediate hosts). Animals become infected by ingesting the larvated eggs or, rarely, the invertebrates. After ingestion, eggs hatch; larvae penetrate the intestinal wall and migrate via the bloodstream to the lungs and moult and reach their sexual maturity after 3 to 6 weeks post-infection (Anderson 2000; Traversa et al. 2011). Clinical signs include coughing and sneezing and in severe cases cause chronic respiratory disease. *E. aerophilus* can infect humans, causing bronchitis, coughing, mucoid sputum, blood in the mucous, fever, dyspnea and pulmonary carcinoma-like masses (Lalosević et al. 2008).

Previous studies on carnivores from Patagonia (Argentina and Chile) stated that ascarid species found were *Toxocara* spp. and *Toxascaris leonina* (Aguilera 2001; Alarcón Navarro 2005; Jiménez et al. 2012; Sánchez Thevenet et al. 2003; Stein et al. 1994; Zanini et al. 2006). Species belong to genus *Toxocara* and *Toxascaris* which are zoonotic. Toxocarosis is a major helminth zoonosis. These parasites have an oral–faecal transmission cycle, and humans can be infected by ingestion of larvae in undercooked infected organ or muscle tissues (rare); infective eggs from contaminated soil (gardens, sandpits and playgrounds); from unwashed hands or raw vegetables or by direct contact with pets (Overgaauw and van Knapen 2013). A number of different syndromes have been attributed to *Toxocara* spp. and *Toxascaris* spp. infection: visceral larva migrans (VLM), ocular larva migrans (OLM) and covert toxocarosis (CT). In addition, associations with neurological and atopic symptoms have also been described.

The study of parasites in animal coprolites has developed over the past decades worldwide. However, few studies have been published on the parasites found in carnivore coprolites. There are only two previous palaeoparasitological studies on carnivores from Patagonia. Fugassa et al. (2006) examined one canid coprolite dated at 6540 ± 110 B.P. probably belonging to *L. culpaeus* collected from the Perito Moreno National Park, Santa Cruz, Argentina. Eggs of nematodes identified as *Trichuris* spp., *Capillaria* spp., *Uncinaria* sp. and an ascarid (probably *Toxascaris* sp.) or spirurids (presumably *Physaloptera* sp.), and one cestode (Anoplocephalidae), presumably *Moniezia* sp., were found. The second study examined feline coprolites from Perito Moreno National Park, Santa Cruz Province, Argentina. Eggs compatible to *Trichuris* sp., *Calodium* sp., *Eucoleus* sp., *Nematodirus* sp., *Oesophagostomum* sp. (Nematoda), *Monoecocestus* sp. (Cestoda) and *Eimeria macusaniensis* (Coccidia) were recovered (Fugassa et al. 2009).

The main faunal resources exploited by humans from ECh were *L. guanicoe*, *C. villosus* and eggs of Rheidae. Carnivores also seem to have been an occasional resource, possibly not only for nutrients (e.g. defleshing marks in *Lycalopex* sp. and *G. cuja*) but also for skins, as evidenced by skinning marks in the mandible of *L. geoffroyi*. In addition, evidences of *L. griseus* died naturally in situ were found, reinforcing the idea of the use of the cave as a shelter by carnivores (Fernández et al. 2016). Zooarchaeological studies of Epullán Grande revealed a human subsistence similar to that recorded in ECh, mostly focussed on the consumption of large-sized mammals (*L. guanicoe*), and an increase through time of a complementary source of food integrated by large-sized birds (*R. pennata*) and medium-sized (*L. griseus* and *L. culpaeus*, *C. chinga* and *C. villosus*) and micro-sized mammals (the tuco-tucos *Ctenomys* spp., and the cavies *G. leucoblephara* and *M. australis*) (Cordero 2009; Crivelli Montero et al. 1996). These evidences show the close

interaction of human with carnivores and therefore the exposition to the zoonoses previously mentioned.

Zooarchaeological evidence from ECh also includes freshwater mollusc shells (*D. chilensis*) reflecting that the freshwater ecosystems were part of the subsistence patterns of the Late Holocene hunter-gatherers of the middle Limay River basin (Fernández et al. 2016). Hunter-gatherers from ECh could be infected by *Paragonimus* if they have the practice of hunting crustaceans in the close rivers.

There are ~1400 known species of human pathogens, including viruses, bacteria, fungi, protozoa and helminths (Taylor et al. 2001). Of these, 65 % are zoonotic and 177 species are responsible for emerging infectious diseases (Dutour 2013). Results displayed in the present study are in line with the reconstruction of the scenario of zoonoses in the past and the diseases that the human populations and animals from Patagonia could be exposed. The present study constitutes the first palaeoparasitological report of carnivore coprolites recovered from the archaeological site ECh and reflects contamination of the cave used by hunter-gatherers with different parasites causative of zoonotic diseases.

References

- Acha P, Szyfres B (2003) Zoonosis y enfermedades transmisibles comunes al hombre y a los animales. In: Parasitosis, vol III, 3rd edn. PAHO, Washington DC, pp. 158–164
- Aguilera J (2001) Estudio preliminar de equinococosis y helmintiasis gastrointestinal en zorro gris (*Pseudalopex griseus*) silvestre de Tierra del Fuego. Chile. Memoria de Título, Escuela de Medicina Veterinaria, Universidad de Concepción, Chillán, Chile
- Alarcón Navarro U (2005) Estudio taxonómico de la fauna parasitaria del tracto gastrointestinal de zorro gris (*Pseudalopex griseus*, Gray 1837), en la XII Región de Magallanes y Antártica Chilena. Memoria de Título. Escuela de Medicina Veterinaria, Universidad Austral de Chile, Valdivia, Chile
- Amin OM (2013) Classification of the Acanthocephala. *Fol Parasitol* 60: 273–305
- Anderson RC (2000) Nematode parasites of vertebrates. Their development and transmission. CABI Publishing, Guilford, UK
- Anderson RC, Chabaud AG, Willmott S (2009) Keys to the nematodes parasites of vertebrates. CABInternational, Wallingford, UK
- Andres JM, English JE, Greiner EC (2014) Acanthocephalan infection probably associated with cockroach exposure in an infant with failure-to-thrive. *Ped. Infect Dis* 6:63–65
- Barquez RM, Díaz MM, Ojeda RA (2006) Mamíferos de Argentina. Sistemática y distribución. SAREM, Argentina
- Beldoménico PM, Kinsella JM, Uhart MM, Gutierrez GL, Pereira J, del Valle Ferreyra H, Marull CA (2005) Helminths of Geoffroy's cat, *Oncifelis geoffroyi* (Carnivora, Felidae) from the Monte desert, central Argentina. *Acta Parasitol* 50:263–266
- Beltrame MO, Fernández FJ, Sardella NH (2015) First paleoparasitological record of acanthocephalan eggs from Northwestern Patagonia (Late Holocene, Argentina). *Acta Trop* 146:33–35
- Blair D, Chang Z, Chen M, Cui A, Wu B, Agatsuma T, Iwagami M, Corlis D, Fu C, Zhan X (2005) *Paragonimus* Skrjabini Chen, 1959

- (Digenea: Paragonimidae) and related species in eastern Asia: a combined molecular and morphological approach to identification and taxonomy. *Sys Parasitol* 60:1–21
- Bowman DD, Montgomery SP, Zajac AM, Eberhard ML, Kazacos KR (2010) Hookworms of dogs and cats as agents of cutaneous larva migrans. *Trends Parasitol* 26:162–167
- Bueno-Marí R, Paulo Gouveia Almeida A, Navarro JC (2015) Emerging zoonoses: eco-epidemiology, involved mechanisms, and public health implications. *Front Public Health* 3:157
- Castillo DF, Luengos Vidal EM, Casanave EB, Lucherini M (2014) Feeding habits of Molina's hog-nosed skunk in the Pampas grassland of Argentina. *Mammalia* 78:473–479
- Chame M (2003) Terrestrial mammal feces: a morphometric summary and description. *Mem Inst Oswaldo Cruz* 98:71–94
- Clelland LM, Reichard MV, Tito RY, Reinhard KJ, Lewis CM (2013) Clarifying prehistoric parasitism from a complementary morphological and molecular approach. *J Archaeol Sci* 40:3060–3066
- Cordero A (2009) Arqueofauna de las primeras ocupaciones de cueva Epullán Grande. *Cuad Antropol* 5:159–188
- Crivelli Montero E, Pardiñas UFJ, Fernández M, Bogazzi M, Chauvin A, Fernández V, Lezcano M (1996) La Cueva Epullán Grande (Provincia de Neuquén, Argentina). Informe de Avance. *Præhistoria* 2:185–265
- Diaz JH (2013) Paragonimiasis acquired in the United States: native and nonnative species. *Clin Microbiol Rev* 26:493–504
- Donadio E, Di Martino S, Aubone M, Novaro AJ (2004) Feeding ecology of the Andean hog-nosed skunk (*Conepatus chinga*) in areas under different land use in north-western Patagonia. *J Arid Environ* 56:709–718
- Dutour O (2013) Paleoparasitology and paleopathology. Synergies for reconstructing the past of human infectious diseases and their pathocenosis. *Int J Paleopathol* 3:145–149
- Dyer WG (1970) Helminths of the striped skunk, *Mephitis mephitis* Schreber, in North Dakota. *Proc Helminthol Soc Wash* 37:92–93
- Fernández FJ, del Papa LM, Mange E, Teta P, Crivelli Montero E, Pardiñas UFJ (2016) Human subsistence and environmental stability during the last 2200 years in Epullán Chica cave (northwestern Patagonia, Argentina): a perspective from the zooarchaeological record. *Quat Internat* 391:38–50
- Ferreira LF (2014) An introduction to paleoparasitology. In: Ferreira LF, Reinhard K, Araújo A (eds), *Foundations of paleoparasitology*. Fiocruz/International Federation of Tropical Medicine, pp. 27–41
- Fugassa MH, Denegri GM, Sardella NH, Araújo A, Guichón RA, Martínez PA, Civalero MT, Aschero C (2006) Paleoparasitological records in a canid coprolite from Patagonia, Argentina. *J Parasitol* 92:1110–1113
- Fugassa MH, Araujo A, Sardella NH, Denegri GM, Guichón RA (2007) New paleoparasitological findings in caves from Patagonia, Argentina. *Paleopathol News* 137:17–21
- Fugassa MH, Beltrame MO, Bayer MS, Sardella NH (2009) Zoonotic parasites associated with felines from the Patagonian Holocene. *Mem Inst Oswaldo Cruz* 104:1177–1180
- Fugassa MH, Reinhard KJ, Johnson KL, Vieira M, Araújo A (2011) Parasitism of prehistoric humans and companion animals from Antelope Cave Mojave County, Arizona. *J Parasitol* 97:862–867
- Gomes APN, Olifiers N, Souza JGR, Barbosa HS, D' Andrea PS, Maldonado A (2015) A new acanthocephalan species (Acanthocephala: Oligacanthorhynchidae) from *Cerdocyon thous*, a crab-eating fox in the Brazilian pantanal wetlands. *J Parasitol* 101:74–79
- Gomez-Puerta LA, Ticona DS, Lopez-Urbina MT, González AE (2009) The Andean hog-nosed skunk *Conepatus chinga* Molina, 1782 as a new definitive host for *Spirometra erinacei* Faust, Campbell and Kellog, 1929. *Vet Parasitol* 160:334–336
- Gomez-Puerta LA, Ticona DS, Lopez-Urbina MT, Gonzalez AE (2012) A new species of *Atriotaenia* (Cestoda: Anoplocephalidae) from the hog-nosed skunk *Conepatus chinga* (Carnivora: Mephitidae) in Perú. *J Parasitol* 98:806–809
- Horne PD (1985) A review of the evidence of human endoparasitism in the pre-Columbian new world through the study of coprolites. *J Archaeol Sci* 12:299–310
- Hunter L (2011) *Carnivores of the world*. Princeton University Press, Princeton
- Jay MT (1996) Zoonotic diseases of carnivores and occupational safety issues for predator control employees. In: Crabb C (ed) *Proceedings of the 17th Vertebrate Pest Conference*. University of California, Davis, pp. 63–67
- Jiménez JE, Briceño C, Alcaíno H, Vásquez P, Funk S, González-Acuña D (2012) Coprologic survey of endoparasites from Darwin's fox (*Pseudalopex fulvipes*) in Chiloé, Chile. *Arch Med Vet* 44:93–97
- Kennedy CR (2006) *Ecology of the Acanthocephala*. Cambridge University Press, The Edinburg Building, Cambridge, New York
- Kruuk H (1986) Interactions between felidae and their prey species: a review. In: Miller SD, Everett DD (eds) *Cats of the world: biology, conservation, and management*. National Wildlife Federation, Washington D.C, pp. 333–352
- Lalosević D, Lalosević V, Klem I, Stanojev-Jovanović D, Pozio E (2008) Pulmonary capillariasis miming bronchial carcinoma. *AmJTrop Med Hyg* 78:14–16
- Lattés S, Ferté H, Delaunay P, Depaquit J, Vassallo J, Vittier M, Kokcha S, Coulibaly E, Marty P (2011) *Trichostrongylus colubriformis* nematode infections in humans, France. *Em. Infect Dis* 17:1301–1302
- Lincoln RC, Anderson RC (1972) The relationship of *Physaloptera maxillaris* (Nematoda:Physalopteroidea) to skunk (*Mephitis mephitis*). *Can J Zool* 51:437–441
- Lutz A (1919) *Schistosoma mansoni* e a schistosomatose segundo observações feitas no Brasil. *Mem Inst Oswaldo Cruz* 1:121–155
- Medina CE, Diaz CV, Delgado FA, Ynga GA, Zela HF (2009) Diet of *Conepatus chinga* (Carnivore: Mephitidae) in a *Polylepis* forest of the Department of Arequipa, Peru. *Rev Peru Biol* 16:183–186
- Mohamadain HS, Ammar KN (2012) Redescription of *Physaloptera praeputialis* von Linstow, 1889 (Nematoda: Spirurida) infecting stray cats (*Felis catus* Linnaeus, 1758) in Qena, Egypt and overview of the genus taxonomy. *J Egyptian Soc Parasitol* 42:675–690
- Moore JG, Fry GF, Englert EJ (1969) Thorny-headed worm infection in North American prehistoric man. *Science* 163:1324–1325
- Moro P, Ballarta J, Gilman R, Leguia G, Rojas M, Montes G (1998) Intestinal parasites of the grey fox (*Pseudalopex culpaeus*) in the central Peruvian Andes. *J Helminthol* 72:87–89
- Naem S, Asadi R (2013) Ultrastructural characterization of male and female *Physaloptera rara* (Spirurida: Physalopteridae): feline stomach worms. *Parasitol Res* 112:1983–1990
- Neiswenter SA, Pence DB, Dowler RC (2006) Helminths of sympatric striped, hog-nosed and spotted skunks in west-central Texas. *J Wild Dis* 42:511–517
- Núñez MB, Bozzolo L (2006) Diet analysis of gray fox, *Pseudalopex griseus* (Canidae) (Gray, 1869), in Sierra de las Quijadas National Park, San Luis, Argentina. *Gayana* 70:163–167
- Ortlepp RJ (1922) The nematode genus *Physaloptera* Rudolphi, 1819. *Proc Zool Soc London* 4:999–1107
- Overgaauw PAM, van Knipen F (2013) Veterinary and public health aspects of *Toxocara* spp. *Vet Parasitol* 193:398–403
- Presidente JJA, Ramsden RO (1975) *Paragonimus kellycotti* infections in wild carnivores in southwestern Ontario: II. Histopathologic features *J Wild Dis* 11:364–375
- Procop GW (2009) North American Paragonimiasis (caused by *Paragonimus kellycotti*) in the context of global paragonimiasis. *Clin Microbiol Rev*:415–446
- Quadros RM, Tietz Marques SM, Moura AB, Antonelli M (2014) First report of the nematode *Physaloptera praeputialis* parasitizing a jaguarundi. *Neotrop. Biol Conserv* 9:186–189

- Reinhard KJ (1992) Parasitology as an interpretative tool in archaeology. *Am Antiq* 57:231–245
- Salehabodi A, Mowlavi G, Sadjjadi S (2008) Human infection with *Moniliformis moniliformis* in Iran: another case report after three decades. *Vector Borne Zoonotic Dis* 8:101–103
- Sánchez Thevenet P, Jensen O, Mellado I, Torrecillas C, Rasos A, Flores ME, Minvielle MC, Basualdo JA (2003) Presence and persistence of intestinal parasites in canine fecal material collected from the environment in the Province of Chubut, Argentine Patagonia. *Vet Parasitol* 117:263–269
- Sarmiento L, Tantaleán M, Huiza A (1999) Nematodos parásitos del hombre y de los animales en el Perú. *Rev Per Parasitol* 14:9–65
- Sato M, Yoonuan T, Sanguankiat S, Nuamtanong S, Pongvongsa T, Phimmayoi I, Phanhanan V, Boupba B, Moji K, Waikagul J (2011) Human *Trichostrongylus colubriformis* infection in a rural village in Laos. *AmJTrop Med Hyg* 84:52–54
- Sianto L, Chame M, Silva CSP, Gonçalves MLC, Reinhard K, Fugassa MH, Araújo A (2009) Animal helminths in human archaeological remains: a review of zoonoses in the past. *Rev Inst Med Trop São Paulo* 51:119–130
- Soibelzon L, Prevosti FJ (2007) Los carnívoros (Carnivora, Mammalia) terrestres del cuaternario de América del Sur, in: Geomorfología Litoral i Quaternari. Homenatge a D. Joan Cuerda Barceló (Gons G.X. and Vicens D. eds). *Mon Soc Hist Nat Balears* 12:5–12
- Stein M, Suriano D, Novaro A (1994) Nematodes parásitos de *Dusycion griseus* (Gray, 1837), *D. culpaeus* (Molina, 1782) y *Conepatus chinga* (Molina, 1782) (Mamífera: Carnívora) en Neuquén, Argentina: Sistemática y ecología. *Bol Chil Parasitol* 49:60–65
- Taylor LH, Latham SM, Woolhouse MEJ (2001) Risk factors for human disease emergence. *Phil Trans R Soc Lond B Biol Sci* 356:983–989
- Traversa D, Di Cesare A, Lia RP, Castagna G, Meloni S, Heine J, Strube K, Milillo P, Otranto D, Meckes O, Schaper R (2011) New insights into morphological and biological features of *Capillaria aerophila* (Trichocephalida, Trichuridae). *Parasitol Res* 109:97–104
- Traversa D, Frangipane di Regalbono A, Di Cesare A, La Torre F, Drake J, Pietrobelli M (2014) Environmental contamination by canine geohelminths. *Parasit Vectors* 7:67
- Uchôa CMA, Mattos Junior CMS, Barcelos AV (1998) Occurrence and identification of *Uncinaria* (Frohlich, 1789) (Nematoda: Ancylostomidae) parasites in stray cats (*Felis catus*) from Rio de Janeiro-Brazil. *Rev Brasil Parasitol Vet* 7:161–164
- Vega R, Brugni N, Schiaffini M, Flores V (2014) Nematodes parásitos de *Conepatus chinga* (Carnívora, Mephitidae) de la Provincia del Chubut. XVII Jornadas Nacionales de Mastozoología, Esquel, Argentina. Libro de Resúmenes, p. 173.
- Vieira FM, Luque JL, Muniz-Pereira LC (2008) Checklist of helminth parasites in wild carnivore mammals from Brazil. *Zootaxa* 1721:1–23
- Walker RS, Novaro AJ, Perovic PA, Palacios R, Donadio E, Lucherini MP, López MS (2007) Diets of three species of andean carnivores in high-altitude deserts of Argentina. *J Mammal* 88:519–525
- Zanini F, Laferrara M, Bitsch M, Pérez H, Elissondo M (2006) Epidemiological studies on intestinal helminth parasites of the patagonian grey fox (*Pseudalopex griseus*) in Tierra del Fuego, Patagonia Argentina. *Vet Parasitol* 136:329–334
- Zapata SC, Travaini A, Delibes M, Martínez-Peck R (2005) Food habits and resource partitioning between grey and culpeo foxes in south-eastern Argentine Patagonia. *Stud Neotrop Fauna Environ* 40:97–103