

The potential use of *Rattus norvegicus* (Mammalia, Muridae) in experimental infections with metacercariae of *Paragonimus mexicanus* (Digenea, Troglotematidae)

Uso potencial de *Rattus norvegicus* (Mammalia, Muridae) en infecciones experimentales con metacercarias de *Paragonimus mexicanus* (Digenea, Troglotematidae)

Hernández-Chea Roderico^{1,3}, Jiménez-Rocha Ana², Rubi Randall², and Dolz Gaby^{1,2}

ABSTRACT: Seven Wistar rats (*Rattus norvegicus*) were experimentally infected with *Paragonimus mexicanus* metacercariae, obtained from organs and tissues of freshwater crabs (Brachyura: Pseudothelphusidae) collected from the Caribbean of Costa Rica. Four rodents were infected orally and three by intraperitoneal injection. Eggs of *P. mexicanus* were found in a stool sample five months post-infection in one of the rodents infected intraperitoneally. Five out of seven rats, developed worms, three immature, and two adult ones. Worms obtained from rats infected intraperitoneally showed development of gonads with presence of eggs in the uterus. Although the recovery rate of worms was low (media: 2.3%), the susceptibility of these rodents to this trematode species was demonstrated as mature adults of *P. mexicanus* were obtained from Wistar rats. The use of Wistar rats as an animal model for experimental infections in further investigations is recommended.

Keywords: intraperitoneal infection, oral infection, metacercariae, *Paragonimus mexicanus*, Wistar rats.

RESUMEN: En este estudio se realizó la infección experimental de siete ratas Wistar (*Rattus norvegicus*) con metacercarias de *Paragonimus mexicanus*, extraídas de órganos y tejidos de cangrejos de agua dulce (Brachyura: Pseudothelphusidae) recolectados en el Caribe costarricense. Cuatro roedores fueron infectados por vía oral y tres, por vía intraperitoneal. En uno de los roedores infectados por vía intraperitoneal se detectó la presencia de huevos en heces, cinco meses post-infección. Cinco de siete roedores desarrollaron formas inmaduras (3) y formas adultas (2). Los gusanos adultos extraídos de las ratas infectadas por vía intraperitoneal, presentaron desarrollo de gónadas con presencia de huevos en el útero. Aunque la tasa de recuperación de gusanos fue baja (media: 2.3%), se demostró la susceptibilidad de las ratas Wistar a esta especie de trematodo, considerando que se obtuvieron gusanos adultos de *P. mexicanus*. Se recomienda el uso de la rata Wistar como modelo animal para infecciones experimentales en futuras investigaciones.

Palabras clave: infección intraperitoneal, infección oral, metacercarias, *Paragonimus mexicanus*, ratas Wistar.

INTRODUCTION

The lung fluke *Paragonimus mexicanus* Myazaki and Ishi 1968, is a food-borne trematode and the causal agent of paragonimiasis in Central América (Hernández-Chea *et al.*, 2017). Humans acquire the infection by eating raw or undercooked freshwater crabs infected with metacercariae (Procop, 2009). The infection in humans produces chronic pneumonia and is characterized by hemoptysis, fatigue, and pulmonary pleural effusion. Ectopic paragonimiasis is the aberrant migration of the parasite to different organs, and in the worst cases may result in cerebral

paragonimiasis (Cha *et al.*, 1994).

Adults of *P. mexicanus* are found in lung cysts of carnivorous mammals such as raccoons (*Procyon lotor* Linnaeus), felids, canids, and marsupials (opossums) that serve as definitive hosts. Small mammals such as rats may act as paratenic hosts in wild environments, hosting metacercariae or immature parasite stages, which may infect final hosts (Miyazaki, 1991).

An animal experimental model is necessary for developing adults of *Paragonimus* in the laboratory. Such models can be used for morphological and molecular characterization of the worms, for antigen

¹Maestría en Enfermedades Tropicales, Posgrado Regional en Ciencias Veterinarias Tropicales, Universidad Nacional, Campus Benjamín Núñez, Barreal de Heredia, Costa Rica

²Escuela de Medicina Veterinaria, Universidad Nacional, Campus Benjamín Núñez, Barreal de Heredia, Costa Rica

³Dirección de Investigación y Extensión, Facultad de Medicina Veterinaria y Zootecnia, Universidad de San Carlos, Edificio M-7, 3° nivel, Ciudad Universitaria, Zona 12, Ciudad de Guatemala, Guatemala.

production, characterization and expression, and for development of specific diagnostic tests (Singh *et al.*, 2011). Experimental infections with *Paragonimus westermani* Kerbert 1878 and *Paragonimus heterotremus* Chen and Hsia 1964 (Sugiyama *et al.*, 1990; Fan *et al.*, 1993) have been carried out in several studies with dogs, cats, and rodents. To date, there is a single report on experimental infection of rats with *P. mexicanus* from which, immature worms from muscle tissue were recovered (Miyazaki, 1991). Among the advantages of using laboratory rodents, instead of dogs and cats, are their low maintenance costs and the fact that their use does not entail ethical conflicts (Narain *et al.*, 2003).

The use of different inoculation routes is also important in experimental infections, as it has been proven that the number of immature worms and the development of adults may be greater if certain routes, such as the intraperitoneal one is used (Habe, 1996).

The objective of this study was to determine the susceptibility of *Rattus norvegicus* Berkenhout, to *P. mexicanus* metacercariae, and to characterize morphologically the worms developed in rodents.

MATERIALS AND METHODS

Study site

Collection of freshwater crabs was carried out during March 2015, at Veragua Rainforest Research and Adventure Park on the Caribbean coast of Costa Rica, in the province of Limón (9° 55' 33.06"N, 83°11' 27.52"W). The sampling locality, Veragua Park, was selected due to its environmental characteristics and the abundance of the freshwater crab *Ptychophallus uncinatus* (Magalhães *et al.*, 2015).

Extraction of metacercariae

Freshwater crabs of the species *Ptychophallus uncinatus* Campos and Lemaitre were collected from

streams of Veragua Park. Male crabs were identified by the morphological appearance of the gonopods. Dissection was performed by cutting and removing the cephalothorax, organs and soft tissues were extracted and placed on Petri dishes with 0.9% saline solution for examination under the stereoscope. Six of the extracted metacercariae were confirmed as *P. mexicanus* through molecular and phylogenetic analysis of segments of the 28S rDNA, ITS2 and *cox1* regions (GenBank Accession Numbers: KX289332-KX289337, KX379696-KX379701, and KX344899-KX344904, respectively) (Hernández-Chea *et al.*, 2017). The remaining 220 metacercariae were stored with 0.9% saline solution at 4°C until they were inoculated into the rodents.

Infection of rodents

Seven Wistar rats (*R. norvegicus*), four males and three females, all 75 days old, were used for experimental infections. Experimental specimens belonged to two different litters at birth (Group N° 1: four males / Group N° 2: three females). Rats were accommodated in the animal building at the School of Veterinary Medicine (Universidad Nacional). All rodents were kept in cages with food and water *ad libitum* under biosafety conditions, previous to and during the experiment. Group 1 was inoculated orally using a Pasteur pipette and Group 2 was infected by intraperitoneal injection. In both cases, each inoculum contained 2ml of 0.9% saline solution and 30 to 35 *P. mexicanus* metacercariae. Rodents inoculated intraperitoneally were sacrificed five months post-infection (pi), while those infected orally were sacrificed seven pi (two individuals), and nine pi (two individuals) (Table 1). A stool sample was taken before each individual was sacrificed, and sedimentation technique was used to detect trematode eggs. Animals were sacrificed by CO₂ inhalation. Necropsies were

Table 1. Data of experimental infection of Wistar rats with *Paragonimus mexicanus* metacercariae.

Rat	Sex	Infection route	Necropsy (months post-infection)	Number of metacercariae inoculated	Number of metacercariae inoculated	Number of recovered worms	% Recovery	Developmental stage
1	M	Oral	9	Pleural cavity	30	1	3.3	Immature worm
2	M	Oral	9	Pleural cavity	35	1	2.8	Immature worm
3	M	Oral	7	Cyst in lung parenchyma	30	0	0	—
4	M	Oral	7	Cyst in lung parenchyma	30	1	3.3	Immature worm
5	F	Intraperitoneal	5	Pleural cavity	30	1	3.3	Adult
6	F	Intraperitoneal	5	Cyst in lung parenchyma	30	1	3.3	Adult
7	F	Intraperitoneal	5	Cyst in lung parenchyma	35	0	0	—
Total					220	5	Media: 2.3	

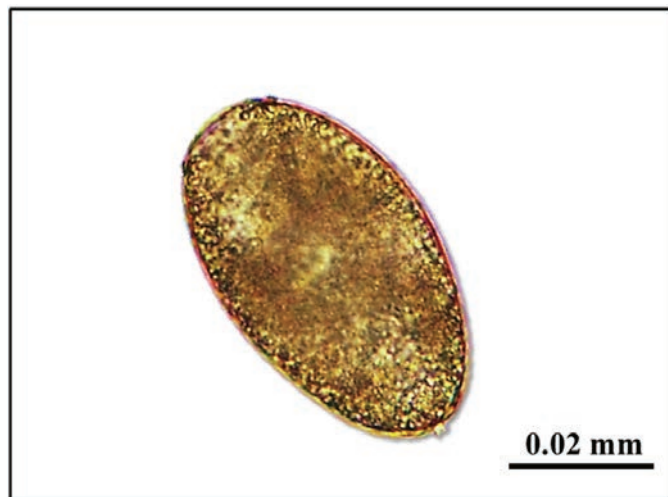


Figure 1. *Paragonimus mexicanus* egg found in a stool sample of an infected Wistar rat.

subsequently performed, and the abdominal organs and lungs were examined. The cysts found in the lungs were carefully cut, worms were extracted, and washed twice with 0.9% saline solution. To determine the developmental stage of the recovered worms, classification criteria *sensu* Shibahara (1984) was used.

Staining and fixation of adult worms

Three of the recovered worms were placed on glass slides and refrigerated at 4°C for 30 minutes. They were immersed in AFA (95 ml alcohol 70%, 3 ml formalin 10%, 2 ml acetic acid) for 12 hours, then stained with Hydrochloric Carmine (200 ml alcohol 90%, 5 ml distilled water, 5 ml hydrochloric acid, 5 g carmine), and mounted in Canada balsam (Castro and Guerrero, 1961).

An adult worm extracted from an infected rat intraperitoneally was examined using a Scanning Electron Microscope (Hitachi TM 3000), and morphology of the oral and ventral sucker, and tegumentary spines were characterized. The worm was previously washed twice with 0.9% saline solution, and fixed in 80% glutaraldehyde, 10% paraformaldehyde, and 10% phosphate buffer (pH 7.2) for two minutes, and finally dried at room temperature for five minutes.

RESULTS

Recovery of worms

Five Wistar rats from a total of seven were positive for the presence of worms in their thoracic cavities or cysts in the lungs (5/7, 71%, Table 1). A total of five *P. mexicanus* worms were recovered. Three immature worms were recovered from rats infected through the oral route (rats N° 1, 2, and 4; Table 1), and two adult worms were recovered from rats infected through the intraperitoneal route (rats N° 5, and 6; Table 1). Although four rats showed cysts in lung parenchyma

(rats N° 3, 7, 4 and 6; Table 1), worms were only found in the latter two. Percentage of worms recovered per infected individual runs from 2.8% to 3.3%, with a mean of 2.3% (Table 1).

Morphology of *P. mexicanus* worms

Eggs of *P. mexicanus* were observed in only one of the stool samples (rat N° 5), in a specimen intraperitoneally inoculated. The eggs had a brown-golden color, were ovoid with a slightly visible operculum, with an average length of 70 µm, and an average width of 4 µm (Fig. 1).

The fixed and stained adult worm (rat N°5) was characterized by light microscopy observations: eggs in the uterus, 6.5 mm body length, 3.75 mm body width, 0.6 mm oral sucker length, 0.68 mm ventral sucker width, 0.66 mm ventral sucker length, and 0.7 mm ventral sucker width (Fig. 2A). Lobed ovary in right position, with some ramifications (Fig. 2C). Lobed testes of similar size, lateral, with some ramifications (Fig. 2B). The fixed and stained immature worm (rat N°4) was characterized by light microscopy observations: 5.6 mm body length, 3.3 mm body width, 0.6 mm oral sucker length, 0.62 mm oral sucker width, 0.62 mm ventral sucker length, and 0.68 mm ventral sucker width (Fig. 2D). This worm was classified as immature *sensu* Shibahara (1984), since rudiments of gonads were visible without spermatozoa, and no eggs were found.

Scanning Electron Microscopy (SEM) of the adult worm

An adult worm (rat N° 6) was characterized (SEM observations): 4.2 mm body length, 1.7 mm body width, 0.47 mm oral sucker width, 0.48 mm oral sucker length, 0.387 mm ventral sucker width, and 0.375 mm ventral sucker length. Ovoid body, with oral sucker (Fig. 3B) larger than ventral sucker; ventral sucker with four external papillae (Fig. 3C). Tegumentary spines like single scales (Fig. 3D) covering the whole body (Fig. 3A).

DISCUSSION

Up to date, *P. mexicanus* experimental infections that developed adult worms have only been successfully reported from domestic cats and dogs (Brenes *et al.*, 1980; Ulate *et al.*, 2015). Huiza *et al.* (2011) only recovered immature worms from orally infected hamsters (*Mesocricetus auratus* Waterhouse), and Miyazaki (1991) also recovered immature specimens from muscle tissue of orally infected rats. So, the recovery of mature specimens of *P. mexicanus* from experimental infections in rats is reported for the first time.

The experimental infections in domestic cats reported a 70% recovery rate for adults (186 inoculated

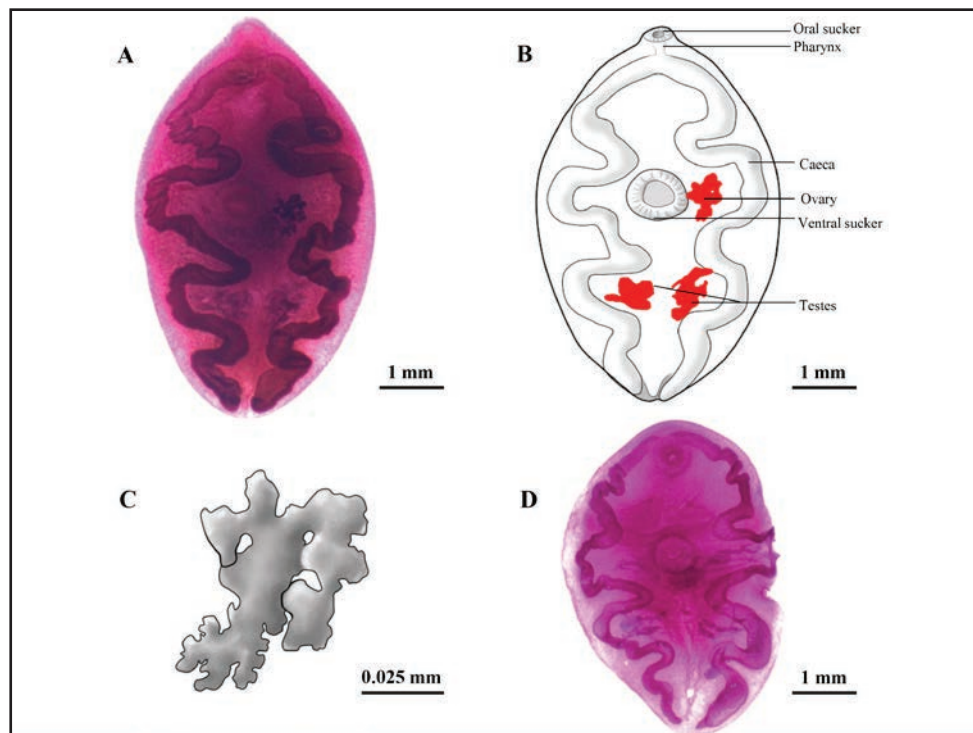


Figure 2. *Paragonimus mexicanus* recovered from experimental infection in Wistar rats. **A.** Mature fluke recovered from intraperitoneal infection (five months pi). **B.** Diagram of the adult fluke. **C.** Diagram of the ovary of the adult fluke. **D.** Immature fluke recovered from oral infection (seven months pi).

metacercariae/131 worms recovered), and 41% in dogs (159/66) (Brenes *et al.*, 1980). Median recovery rate from Wistar rats in this study was lower (2.3%); however, two adults of *P. mexicanus* were recovered from seven infected animals.

Evidence indicates that rodents may act as definitive hosts of *Paragonimus macrorchis* Chen 1962 in Sri Lanka (Kannagara, 1969), and *P. heterotremus* in Vietnam (Narain *et al.*, 2003; Doanh *et al.*, 2015). Also, they may serve as paratenic hosts of *P. westermani* in China (Fan *et al.*, 1993). In this study, it was possible to observe the presence of *P. mexicanus* eggs in a stool sample of an intraperitoneally infected rat, which indicates that under laboratory conditions, and using intraperitoneal injection, it is probable that *R. norvegicus* could serve as definitive host of the lung fluke *P. mexicanus*. However, it was not possible to prove that eggs contained in the uterus were viable and capable of continuing the parasite's cycle, given that only one adult worm was found in each rat, so the eggs might not have been fertilized. The finding of adults of *P. mexicanus* is very important if an experimental infection model with Wistar rats is going to be implemented for use in characterization of antigens and specific diagnostic tests. Under natural conditions, *R. norvegicus* could only ingest *P. mexicanus* metacercariae by consuming infected crabs.

In oral infections only immature worms were recovered, indicating that rats seem to serve as pa-

ratenic hosts of *P. mexicanus* through this route, as was previously shown by Miyazaki (1991). Definitive hosts, such as domestic dogs and cats, become infected when they consume paratenic hosts (Miyazaki, 1991). In that study, only immature worms were recovered from rats infected with *P. mexicanus*, and developed to the adult stage upon the ingestion of the rats by cats. These results are consistent with those reported in this study. Furthermore, it is probable that the susceptibility of hosts may vary depending on the *P. mexicanus* sub-population used in experimental infections, as shown in experimental infections of Wistar rats with *P. heterotremus* of different localities from Asia (Singh and Singh, 1997; Narain *et al.*, 2003).

Comparing to the results obtained by Brenes *et al.* (1980), the adult worms recovered in this study were half the size of those recovered from cats, and also the gonads (primarily the testes) were smaller. This is probably due to the evolutionary adaptation of *P. mexicanus* in carnivorous mammals, specifically in canids and felids.

The adult worm observed by SEM was morphologically similar to those described by Hernandez and Monge (1989), from experimentally infected cats. The tegumentary spines of the adult worm had single scales (flatter spines); meanwhile spines from adults obtained from cats were single tip ones. Similarities in the papillae of the ventral sucker were observed; Hernández and Monge (1989) reported six or seven papillae, nevertheless, they also found specimens

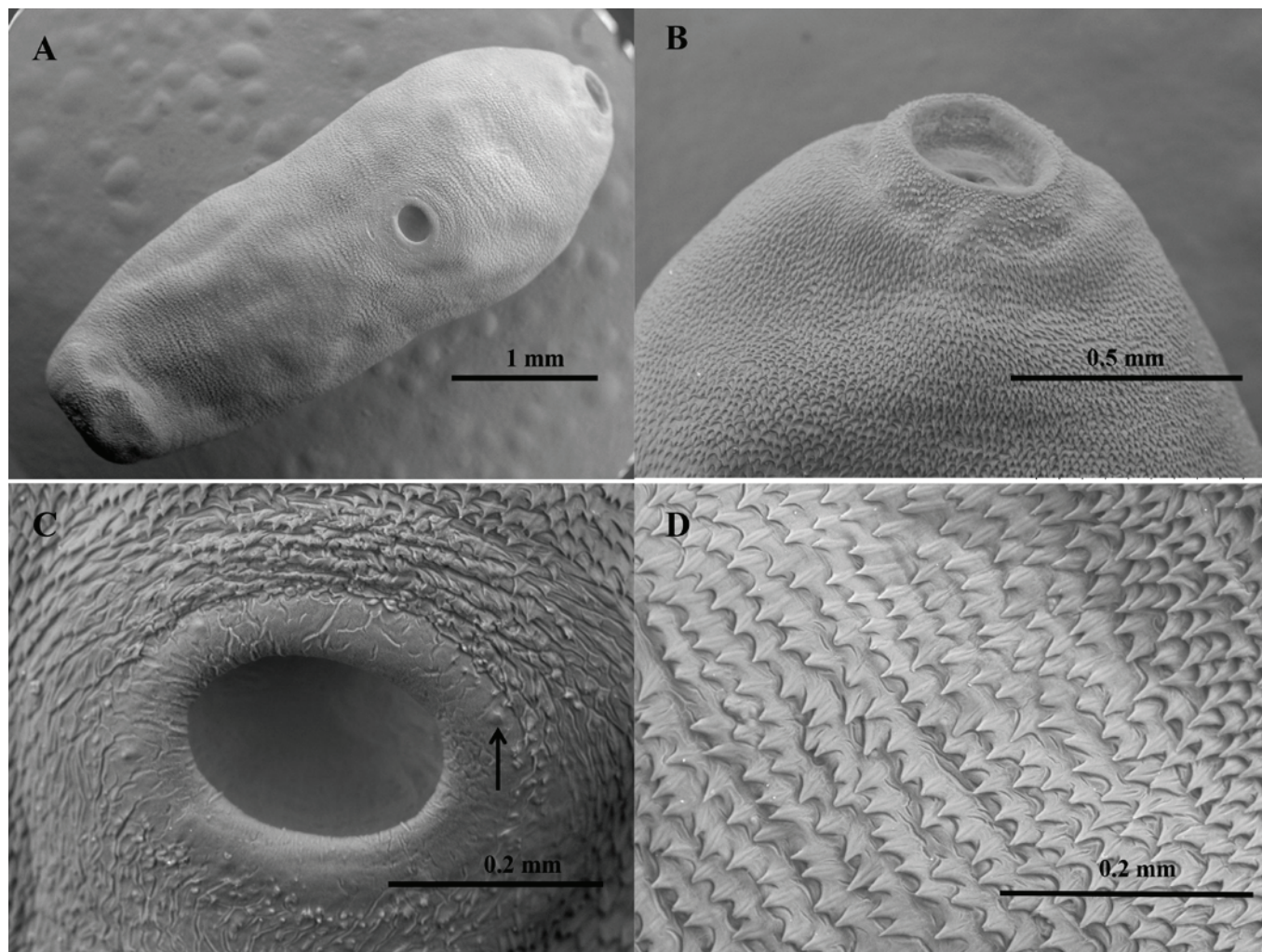


Figure 3. Scanning Electron Microscopy of an adult of *Paragonimus mexicanus* recovered from intraperitoneal infection. **A.** Whole specimen. **B.** Oral sucker. **C.** Ventral sucker with papillae (arrow). **D.** Tegumentary spines.

without papillae, our worm had only four slightly developed papillae. It is necessary to evaluate more specimens of *P. mexicanus* from Costa Rica to detect morphological variation of papillae, and shape of the tegumentary spines.

The two adults with completely developed gonads and eggs in the uterus were recovered from intraperitoneally infected rats. Taking into account these results, we assume that the most convenient route of infection to obtain adult *P. mexicanus* worms is the intraperitoneal injection in rodents, rather than the oral route. In laboratory rats experimentally infected with *P. westermani* and *P. macrorchis*, more adult worms were recovered from intraperitoneally than from orally infected individuals (Kannangara, 1969; Habe *et al.*, 1996). In this study, it was not possible to demonstrate a better recovery of worms in intraperitoneally infected rats, given that for both infection routes the maximum number of worms recovered per infected individual was one.

This study showed the usefulness of Wistar rats as an animal experimental model for recovery of *P. mexicanus* worms. Although the recovery rate was low,

it was possible to recover mature specimens, so this model can be used to carry out investigations about immunological responses, new therapeutic options, characterization of antigenic products secreted by adult worms, and their use in immune-diagnostic specific tests. Furthermore, Wistar rats are convenient laboratory animals, and ethical conflicts related to the use of dogs and cats as experimental animals are reduced.

ACKNOWLEDGEMENTS

We gratefully acknowledge to: Ingo Wehrtmann, Frescia Villalobos and Raquel Romero (CIMAR, Universidad de Costa Rica), for their technical support in the collection of samples and data; Idiania Chacón (Costa Rican Ministry of Agriculture and Livestock), for her collaboration with this study; School of Veterinary Medicine (Universidad Nacional de Costa Rica), for providing the experimental hosts; the technical and office personnel from Veragua Rainforest Research and Adventure Park (Limón, Costa Rica); and, Jorge Hernández (Laboratorio de Parasitología, Escuela de Medicina Veterinaria, Universidad Nacional), for his technical support. Our

special thanks to David Blair (Centre for Tropical Biodiversity and Climate Change, James Cook University, Australia), for his important contributions to this study. Financial support was provided by Concejo Nacional de Rectores (CONARE, Fondos FEES), and Deutscher Akademischer Austauschdienst (DAAD) provided the scholarship to Roderico Hernández Chea.

Experimentation in rats was conducted with the consent of Animal Welfare Committee and Bioethics, School of Veterinary Medicine, Universidad Nacional, Costa Rica (No.03-2014), and in accordance with the corresponding law, Ley de Bienestar de los Animales of Costa Rica (Law 7451 on Animal Welfare).

LITERATURE CITED

- Brenes RR, Zeledón R, Rojas G. 1980. Biological cycle and taxonomy position of Costa Rican paragonimiasis and the present status of *Paragonimus* from the New World. *Brenesia* 18: 353-366.
- Castro A, Guerrero O. 1961. Técnicas de diagnóstico parasitológico. Editorial de la Universidad de Costa Rica. San José, Costa Rica. 99 pp.
- Cha SH, Chang KH, Cho SY, Han MH, Kong Y, Suh DC, Kim MS. 1994. Cerebral paragonimiasis in early active stage: CT and MR features. *American Journal of Roentgenology* 162: 141-145.
- Doanh PN, Hien HV, An PT, Tu LA. 2015. Development of lung fluke, *Paragonimus heterotremus*, in rat and mice, and the role of paratenic host in its life cycle. *Tap Chi Sinh Hoc Journal of Biology* 37: 265-271.
- Fan PC, Lu H, Lin LH. 1993. Experimental infection of *Paragonimus westermani* in mice and rats. *Korean Journal of Parasitology* 31: 91-97.
- Habe S, Lai KP, Agatsuma T, Ow-Yang CK, Kawashima K. 1996. Growth of Malaysian *Paragonimus westermani* in mammals and the mode of transmission of the fluke among mammals. *Japanese Journal of Tropical Medicine and Hygiene* 24: 225-232.
- Hernández F, Monge E. 1989. Cuticular ultrastructure of *Paragonimus* from Costa Rica. *Journal of Electron Microscopy* 38: 41-46.
- Hernández-Chea R, Jiménez-Rocha AE, Castro R, Blair D, Dolz G. 2017. Morphological and molecular characterization of the metacercaria of *Paragonimus caliensis*, as a separate species from *P. mexicanus* in Costa Rica. *Parasitology International* 6:126-133.
- Huiza A, Sevilla C, Espinoza Y. 2001. Infección experimental del hámster (*Mesocricetus auratus*) con metacercarias de *Paragonimus mexicanus* (*peruvianus*). *Revista Peruana de Medicina Experimental y Salud Pública* 18: 3-4.
- Kannangara DWW. 1969. Occurrence of the lung-fluke *Paragonimus macrorchis* Chen, 1962 in Ceylon. *Ceylon Journal of Medical Science* 18: 33-38.
- Magalhães C, Wehrtmann IS, Lara LR, Mantelatto FL. 2015. Taxonomy of the freshwater crabs of Costa Rica, with a revision of the genus *Ptychophallus* Smalley, 1964 (Crustacea: Decapoda: Pseudothelphusidae). *Zootaxa* 3905: 301-344.
- Miyazaki I. 1991. Paragonimiasis. In: Miyazaki I (Ed.). An illustrated book of helminthic zoonoses. International Medical Foundation of Japan Press. Tokyo, Japan: 76-146 (Digitalized Version, Southeast Asian Medical Information Center, Issue 62).
- Narain K, Devi KR, Mahanta J. 2003 A rodent model for pulmonary paragonimiasis. *Parasitology Research* 91: 517-519.
- Procop GW. 2009. North American paragonimiasis (caused by *Paragonimus kellicotti*) in the context of global paragonimiasis. *Clinical Microbiology Reviews* 22: 415-446.
- Shibahara T. 1984. Studies on the lung fluke, *Paragonimus westermani* -diploid type- in the northern part of Hyogo Prefecture, Japan. III. Experimental oral infection with metacercariae of rats with reference to juvenile worms removed from the muscles. *Japanese Journal of Parasitology* 33: 119-132.
- Singh TS, Singh YI. 1997. Three types of *Paragonimus* metacercariae isolated from *Potamiscus manipurensis* in Manipur. *Indian Journal of Medical Microbiology* 15: 159-162.
- Singh TS, Sugiyama H, Devi KR, Singh LD, Binchai S, Rangsiruji A. 2011. Experimental infection with *Paragonimus heterotremus* metacercariae in laboratory animals in Manipur, India. *The Southeast Asian Journal of Tropical Medicine and Public Health* 42: 34-38.
- Sugiyama H, Shibahara T, Katahira J, Horiuchi T, Tomimura T, Agatsuma T, Habe S, Kawashima K, Ketudat P, Thaithong S. 1990. Rats and mice served as experimental paratenic hosts of Thai *Paragonimus heterotremus*. *Japanese Journal of Tropical Medicine and Hygiene* 18: 295-300.
- Ulate E, Rojas G, Hernández-Chea R, Jiménez-Rocha AE, Dolz G. 2015. Diagnosis of human paragonimiasis in Costa Rica using intradermal test and immunoblot. *Journal of Harmonized Research in Medical and Health Sciences* 2: 122-131.

Recibido: 18 de noviembre de 2016
Aceptado: 15 de enero de 2017
