

ULTRASTRUCTURAL CHANGES OF HENLE'S LOOP EPITHELIAL CELLS IN THE KIDNEY OF MICE TREATED WITH LOW DOSES OF OCHRATOXIN A

Jose I. Aguirre, Carlos J. Perfumo, and Julio R. Idiart

Department of Pathology Dr. B. Epstein, Faculty of Veterinary Science, National University of La Plata, Argentina

Shin-ichi Itagaki and Kunio Doi

Department of Biomedical Science, Faculty of Agriculture, The University of Tokyo

Abstract: Renal changes in mice daily treated with low doses of ochratoxin A (OA; 50–400 $\mu\text{g}/\text{kg}$) for up to 4 weeks were investigated by electron microscope. Except the mice treated with 50 $\mu\text{g}/\text{kg}$ of OA for 4 weeks, all treated mice showed the following changes in the epithelial cells of Henle's loop: (1) degeneration of mitochondria, (2) increment of endoplasmic reticula, and (3) increase in the number and size of lysosomes and myelin figures. (J Toxicol Pathol 7: 91~94, 1994)

Key words: Henle's loop, Kidney, Mice, Ochratoxin A, Ultrastructure

Ochratoxin A (OA), a fungal metabolite mainly produced by *Aspergillus ochraceus* and *Penicillium viridicatum*, is present as a contaminant in plant products, especially cereals, beans, and peanuts¹. It has been implicated as an etiologic agent responsible for Balkan nephropathy in humans and acute ochratoxicosis in domestic animals²⁻⁴.

Renal ultrastructural changes experimentally induced by OA have been described in such animal species as goats⁵, dogs^{6,7}, chicks^{8,9}, rats^{10,11}, and mice¹². However, these experiments except ones with chicks were conducted to observe acute lesions by high doses of OA. Thus the purpose of this study is to investigate subacute ultrastructural changes in the kidney of mice daily treated with low doses of OA, which are roughly equivalent to the concentration commonly seen as a contaminant in feed.

Forty-nine 4-week-old ICR: CD-1 male

mice weighing about 20 g (Charles River Japan, Kanagawa) were used in this study. Animals were maintained under controlled conditions (temperature $22 \pm 2^\circ\text{C}$; humidity $55 \pm 5\%$) and fed MF pellets (Oriental Yeast Co. Ltd., Tokyo) and water *ad libitum* throughout the experimental period. Mice were divided into 7 groups according to the dose and inoculation period as follows. Fourteen mice were inoculated with 200 or 400 $\mu\text{g}/\text{kg}$ b.w. of Benzene-free OA (Sigma, St. Louis, MO), dissolved in 0.1 M sodium carbonate, by stomach tube for 2 weeks (6 days per week); 200/2W and 400/2W groups. Twenty-eight mice were inoculated with 50, 100, 200, or 400 $\mu\text{g}/\text{kg}$ b.w. of OA for 4 weeks; 50/4W, 100/4W, 200/4W, and 400/4W groups. Remaining mice were inoculated with 0.2 ml of vehicle for 4 weeks; control group. All animals were sacrificed by heart puncture under ether anesthesia 2 days after the final inoculation. Kidneys were fixed in 10% neutral buffered formalin for light microscopy and 4 μm -paraffin sections were stained with hematoxylin and eosin and periodic acid-Schiff. Small pieces of kidneys were fixed in 2.5% glutaraldehyde and 2% paraformaldehyde in 0.1 M phosphate buffer

板垣慎一 土井邦雄

Accepted for publication: August 19, 1993

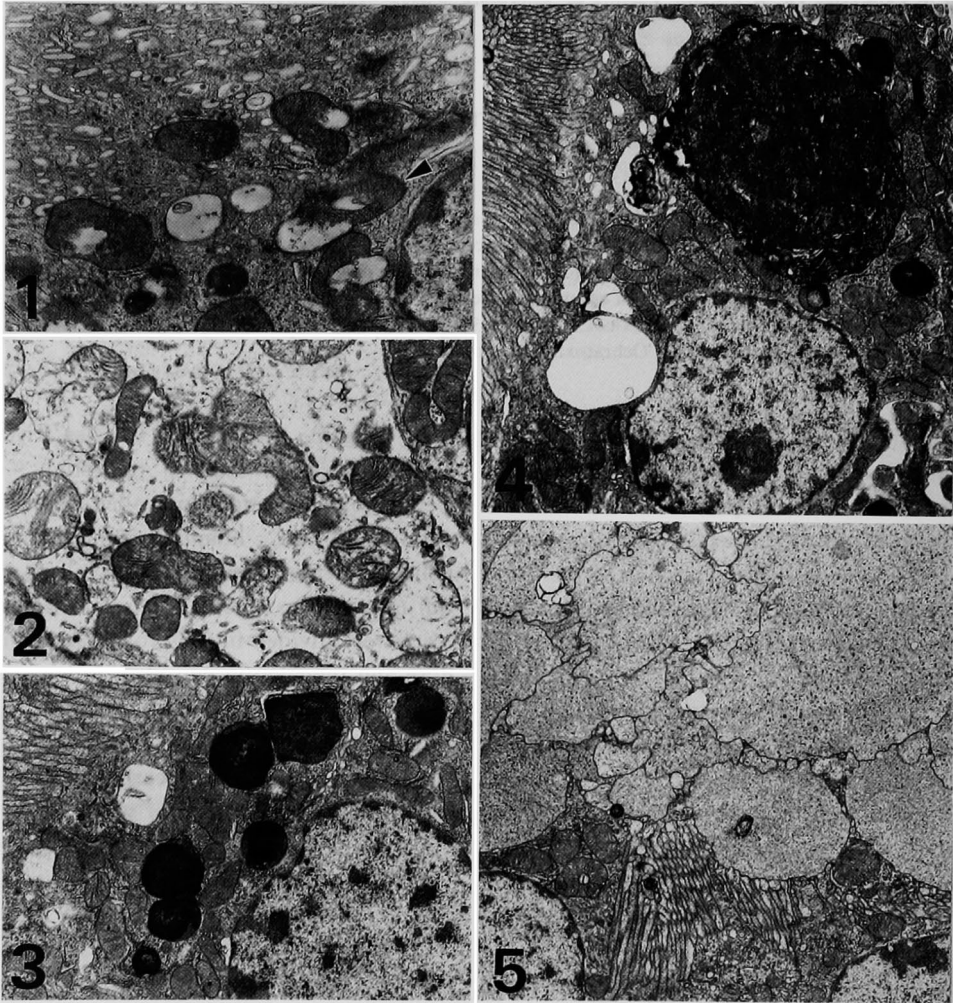
Mailing address: Kunio Doi, Department of Biomedical Science, Faculty of Agriculture, The University of Tokyo, Yayoi 1-1-1, Bunkyo-ku, Tokyo 113, Japan.

(pH 7.4), post fixed in 1.0% osmium tetroxide in the same buffer, and processed for electron microscope. Ultrathin sections were stained with uranyl acetate and lead citrate and observed under a JEM-1200 EX II (JEOL Co. Ltd, Tokyo).

Light microscopically, lesions were detected in the uriniferous tubules only in the 400/4W group. Cellular swelling (hydropic degeneration) was observed in the epithelial cells of straight

descending limbs of Henle's loop in the cortical juxtamedullary zone. Although less frequently, the epithelial cells of thick ascending limbs of Henle's loop also showed similar changes.

Mice in all groups except 50/4W one showed ultrastructural changes mainly in the epithelial cells of Henle's loop. Many mitochondria were abnormal in shape, i.e., elongated, U, or ring form. Prominently degenerated mitochondria showed



- Fig. 1. 400/2W group. Straight descending limb of Henle's loop. Vacuolated mitochondria (below) and many endoplasmic reticula (upper side). Ring-shaped mitochondria (arrowhead). $\times 13,000$.
- Fig. 2. 400/4W group. Straight descending limb of Henle's loop. Swollen and lytic mitochondria in edematous cytoplasm. $\times 9,000$.
- Fig. 3. 400/4W group. Straight descending limb of Henle's loop. Epithelial cell includes large lysosomes. Vacuoles are seen beneath the apical microvilli. $\times 6,500$.
- Fig. 4. 400/4W group. Straight descending limb of Henle's loop. Large myelin figure occupies greater part of cytoplasm. $\times 6,500$.
- Fig. 5. 400/4W group. Straight descending limb of Henle's loop. Desquamated cytoplasm is seen in lumen. $\times 5,000$.

vacuolation, swelling, or lysis. Crista in these degenerated mitochondria were shortened, reduced or disoriented (Figs. 1 and 2). The number of fragmented or vesiculated endoplasmic reticula increased (Fig. 1). Lysosomes and myelin figures also increased in number and size (Fig. 3), and, especially in the 400/4W group, large myelin figures occupied the cytoplasm of some cells (Fig. 4). Large vacuoles were observed mainly beneath the apical microvilli (Figs. 3 and 4). In addition, cells, which were considered to be equivalent to light microscopically swollen cells in the 400/4W group, exhibited intracytoplasmic edema. Parts of cytoplasm of these cells were released and sometimes occupied the lumen (Fig. 5). In the 400/4W group, epithelial cells of collecting ducts also showed similar changes in mitochondria and endoplasmic reticula to those of Henle's loop.

In rats and mice treated with high doses of OA, acute changes were reported to be seen in the urinary tubules¹²⁻¹⁴. However, Albassam *et al.* reported in rats similarly treated with OA that prominent ultrastructural changes were observed in the glomerular capillary endothelial cells, and they did not refer to ultrastructural changes in the urinary tubules¹⁰. Like the former studies on acute toxicity of high doses of OA, the present study clarified that subacute lesions induced by low doses of OA were also seen in the urinary tubules, especially Henle's loop.

Similar changes of mitochondria as seen in this study were also reported in the kidney of goats⁵, dogs^{6,7}, chicks^{8,9}, and mice¹² experimentally intoxicated with OA. OA is known to inhibit enzyme activity in the urinary tubules¹⁵ and mitochondrial respiration¹⁶⁻¹⁸, and mitochondrial dysfunction is said to be an early event during the development of OA toxicity¹⁹. Structural changes of mitochondria seen in many species might account for functional impairment of the kidney in ochratoxicosis. Furthermore, an increase in number and size of myelin figures was also reported in goats⁵ and chicks^{8,9}, and it might result from binding of OA to lipidic membranes, making them difficult to be digested⁵.

OA has strong affinity to the renal organic anion transport system which exists in the brush border and basolateral membrane of urinary

tubule epithelial cells²⁰, and reabsorption via this system may facilitate the residual persistence of OA in the kidney²¹. Ultrastructural changes in the Henle's loop epithelial cells observed in this study may reflect the cell injury caused by reabsorbed and persisted OA.

References

1. Ueno, Y: The toxicology of mycotoxins. *CRC Crit Rev Toxicol* **14**: 99-132, 1985.
2. Castegnaro, M and Chernozemsky, I: Endemic nephropathy and urinary tract tumors in the Balkans. *Cancer Res* **47**: 3608-3609, 1987.
3. Cooper, P: The kidney and ochratoxin A. *Food Cosmet Toxicol* **17**: 406-408, 1979.
4. Pier, AC, Richard, JL, and Cysewski, SJ: Implications of mycotoxins in animal disease. *J Am Vet Med Assoc* **176**: 719-724, 1980.
5. Maryamma, KI and Nair, MK: Ultrastructural pathology of the kidney in experimental ochratoxicosis in goats. *Ind J Anim Sci* **60**: 623-627, 1990.
6. Kitchen, DN, Carlton WW, and Hinsman, EJ: Ochratoxin A and citrinin induced nephrosis in Beagle dogs. III. Terminal renal ultrastructural alterations. *Vet Pathol* **14**: 392-406, 1977.
7. Szczech, GM, Carlton, WW, and Hinsman, EJ: Ochratoxicosis in Beagle dogs. III. Terminal renal ultrastructural alterations. *Vet Pathol* **11**: 385-406, 1974.
8. Brown, TP, Manning, RO, Fletcher, OJ, and Wyatt, RD: The individual and combined effect of citrinin and ochratoxin A on renal ultrastructure in layer chicks. *Avian Dis* **30**: 191-198, 1986.
9. Dwivedi, P, Burns, RB, and Maxwell, MH: Ultrastructural study of the liver and kidney in ochratoxicosis A in young broiler chicks. *Res Vet Sci* **36**: 104-116, 1984.
10. Albassam, MA, Yong, SI, Bhatnager, R, Sharma, AK, and Prior, MG: Histopathologic and electron microscopic studies on the acute toxicity of ochratoxin A in rats. *Vet Pathol* **24**: 427-435, 1987.
11. Suzuki, S, Kozuka, Y, Satoh, T, and Yamazaki, M: Studies on the nephrotoxicity of ochratoxin A in rats. *Toxicol Appl Pharmacol* **34**: 479-490, 1975.
12. Shadmi, A and Nobel, TN: Kidney lesions from mycotoxins as observed by electron microscope. *Ann Rech Vet* **12**: 75-83, 1981.
13. Kanisawa, M, Suzuki, S, Kozuka, Y, and Yamazaki, M: Histopathological studies on the toxicity of ochratoxin A in rats. I. Acute oral toxicity. *Toxicol Appl Pharmacol* **42**: 55-64, 1977.
14. Purchase, IFH and Theron, JJ: The acute toxicity of ochratoxin A to rats. *Food Cosmet Toxicol* **6**: 479-483, 1968.
15. Elling, F: Ochratoxin A-induced mycotoxic porcine nephropathy: alterations in enzyme activity in tubular cells. *Acta Pathol Microbiol Scand Sect A*

- 87: 237-243, 1979.
16. Meisner, H and Chan, S: Ochratoxin A, an inhibitor of mitochondrial transport systems. *Biochemistry* **13**: 2795-2800, 1974.
 17. Moore, JH and Truelove, B: Ochratoxin A: inhibition of mitochondrial respiration. *Science* **168**: 1102-1103, 1970.
 18. Wei, YH, Lu, CY, Lin, TN, and Wei, RD: Effect of ochratoxin A on rat liver mitochondrial respiration and oxidative phosphorylation. *Toxicology* **36**: 119-130, 1985.
 19. Aleo, MD, Wyatt, RD, and Schnellmann, RG: Mitochondrial dysfunction is an early event in ochratoxin A but not oosporein toxicity to rat renal proximal tubules. *Toxicol Appl Pharmacol* **107**: 73-80, 1991.
 20. Sokol, PP, Ripich, G, Holohan, PD, and Ross, CR: Mechanism of ochratoxin A transport in kidney. *J Pharmacol Exp Therapeut* **246**: 460-465, 1987.
 21. Stein, AF, Phillips, TD, Kubena, LF, and Harvey, RB: Renal tubular secretion and reabsorption as factors in ochratoxicosis: effect of probenecid on nephrotoxicity. *J Toxicol Env Health* **16**: 593-605, 1985.