

Effects of equid herpesvirus 1 (EHV-1) AR8 and HH1 strains on BALB-c mice

Carolina Zanuzzi · Mariela Scrochi · Nadia Fuentealba ·
Fabián Nishida · Enrique Portiansky · Cecilia Muglia ·
Eduardo Gimeno · Claudio Barbeito · Cecilia Galosi

Received: 20 March 2013 / Accepted: 31 May 2013 / Published online: 13 July 2013
© Springer-Verlag Wien 2013

Abstract Here, we used a murine model to describe and compare the pathogenic potential of the Argentinean equid herpesvirus 1 (EHV-1) AR8 strain with the Japanese HH1 reference strain. In AR8-inoculated animals, clinical signs began earlier, but the viremic phase was shorter. Virus isolation and DNA detection in the lungs, liver and spleen were positive for both strains at different times postinfection (pi). Infection foci produced by both strains were immunohistochemically detected in lungs from day 1 to day 4 pi. We conclude that whichever EHV-1 strain is selected to experimentally reproduce the disease, it needs appropriate standardization in order to provide valid conclusions.

Much research related to equid herpesvirus 1 (EHV-1) has been carried out using the murine model. Several aspects of the respiratory, neurological and abortigenic forms of the diseases induced by the virus have been described and explained [2, 4, 6, 7, 20–22, 24]. Despite these advances,

most of the studies have been carried out using different viral strains, doses and inoculation routes, making it difficult to compare and extrapolate data. In addition, studies using similar viral or mouse strains have also yielded controversial results regarding histopathological, molecular and clinical aspects [1, 2, 6, 16, 19, 21, 23]. In this work, we describe and compare the behavior of the Argentinean EHV-1 AR8 strain with that of the Japanese HH1 reference strain in mice at different times post-inoculation (pi), using standard virological methods and molecular and immunohistochemical techniques.

The AR8 strain was isolated in 1996 [14, 15], whereas the HH1 strain was isolated from an aborted fetus from a mare with a confirmed EHV-1 infection [13], and since then, it has been used as a reference strain in several studies using the murine model [6, 10, 11]. In the present study, stocks of both strains were prepared in rabbit kidney epithelial cells (RK13) [6], quantified by the standard Reed and Muench method [18], and stored at -70°C until used. Twenty-four six-week-old male specific-pathogen-free

C. Zanuzzi (✉) · C. Barbeito
Department of Histology and Embryology, School of Veterinary
Sciences, National University of La Plata, 60 and 118 streets,
postal code 1900 La Plata, Buenos Aires, Argentina
e-mail: carozanuzzi@gmail.com

C. Zanuzzi · F. Nishida · E. Portiansky · E. Gimeno ·
C. Barbeito
Department of General Pathology, School of Veterinary
Sciences, National University of La Plata, La Plata,
Buenos Aires, Argentina

C. Zanuzzi · M. Scrochi · N. Fuentealba · F. Nishida ·
E. Portiansky · C. Muglia · E. Gimeno · C. Barbeito
National Scientific and Technical Research Council
(CONICET-CCT La Plata), La Plata, Argentina

M. Scrochi · N. Fuentealba · C. Galosi
Department of Virology, School of Veterinary Sciences,
National University of La Plata, La Plata, Buenos Aires,
Argentina

C. Muglia
Department of Biological Sciences, LISIN Laboratory, School of
Exact Sciences, National University of La Plata, 115 and 47
streets, La Plata, Buenos Aires, Argentina

C. Galosi
Scientific Research Commission of Buenos Aires Province
(CIC-PBA), La Plata, Argentina

BALB/c mice were divided into six groups of four animals each (one control animal and three virus-inoculated animals) for each strain and time studied. The procedures were approved by the Institutional Animal Care and Use Committee (CICUAL, Faculty of Veterinary Sciences of La Plata National University, Buenos Aires, Argentina) and performed in accordance with the 'Guide for the Care and Use of Laboratory Animals' (National Academy Press, 1996, Washington, DC, USA).

Animals were anesthetized with isoflurane (Baxter Co., Deerfield, IL, USA), and then inoculated intranasally, either with 30 μ l (~20,000 CCID₅₀) of culture supernatant of AR8- or HH1-infected RK13 cells, or with 30 μ l of supernatant of uninfected cells (one control animal) for each time point studied. At 1, 2, 3, 4, 7 and 10 days pi, virus-inoculated and control animals were deeply anesthetized with isoflurane and killed by exsanguination. Heparinized pooled blood samples (20 IU/ml) were collected at 12 h pi and then approximately every 12 h until the killing time. Samples of plasma rich in leukocytes [6], lungs, liver and spleen were subjected to virus isolation in RK13 cells using standard methodology and then processed for DNA detection by the polymerase chain reaction (PCR) and for histopathological analysis and immunohistochemical determination. Titers from lungs were calculated by the Reed and Muench method and expressed as CCID₅₀/50 μ l. The PCR was performed using a pair of specific oligonucleotide primers that amplified a 369-bp fragment derived from a conserved gC region of EHV-1: 5'-CAAC AATCGGGGAGGCGTCATA-3', position 21582–21603, and 5'-GTAGCATAGACTGGTACAGGGA-3', position 21929–21950. The amplification was conducted following a previously standardized protocol [5]. For histopathological analysis, 3- μ m-thick paraffin-embedded sections of lungs, liver and spleen stained with hematoxylin-eosin were analyzed. Immunohistochemistry (IHC) on these samples was performed as described previously [4] to study the distribution of EHV-1 antigen. The average gain or loss in relative weight was also calculated for each group and strain. In addition, the safety index, a parameter of pathogenicity introduced by van Woensel et al. [21], was calculated. This index was defined as the surface under the relative weight curve for the first 10 days after infection and calculated by adding the individual weight gains from day 1 to day 10 and determining the average weight gain per group. Data were analyzed by one-way analysis of variance (ANOVA). Significance was assumed at values of $p < 0.05$. The Fisher least significant difference (LSD) test was used for *post hoc* comparisons. For these comparisons, a value of $p < 0.01$ was used to define significance between groups.

AR8-inoculated mice showed dyspnea and ruffled fur from day 1 to day 3 pi, whereas HH1-inoculated mice

showed dyspnea from day 3 and ruffled fur from day 2 pi. No significant differences were observed in relative body weight between control mice and AR8- or HH1-inoculated mice. However, the safety index for the HH1 strain was higher (Fig. 1a). No other clinical signs were observed in the remaining virus-inoculated or control animals. Virus isolation from plasma rich in leukocytes was possible on day 1 pi for the AR8 strain, and up to day 2 pi for the HH1 strain. Both strains were recovered from lungs up to day 7 pi, and viral titers reached a peak between day 2 and day 3 pi, in coincidence with the time of maximal expression of clinical signs (Fig. 1b). Virus isolation from the liver and spleen was positive. In liver samples from mice inoculated with each strain, cytopathic effect was observed in RK13 cells up to day 2 pi, whereas in spleen samples, it was detected up to day 2 pi for AR8 and day 3 pi for HH1 (Table 1).

Viral DNA detection was positive in the lungs (1–7 days pi), liver (1–2 days pi), spleen (on day 1 pi for the AR8 strain, and from day 1 to 3 pi for the HH1 strain) and plasma (on day 1 pi for the AR8 strain, and from day 1 to 2 pi for the HH1 strain), of mice inoculated with either strain.

Histological lesions consisting of infection foci were found only in the lungs up to day 4 pi for each strain studied. Lesions were mainly located in the distal bronchial or bronchiolar epithelium. Desquamated cells with disrupted nuclei showing marginal chromatin, few syncytia, and mild lymphocytic infiltration surrounding respiratory

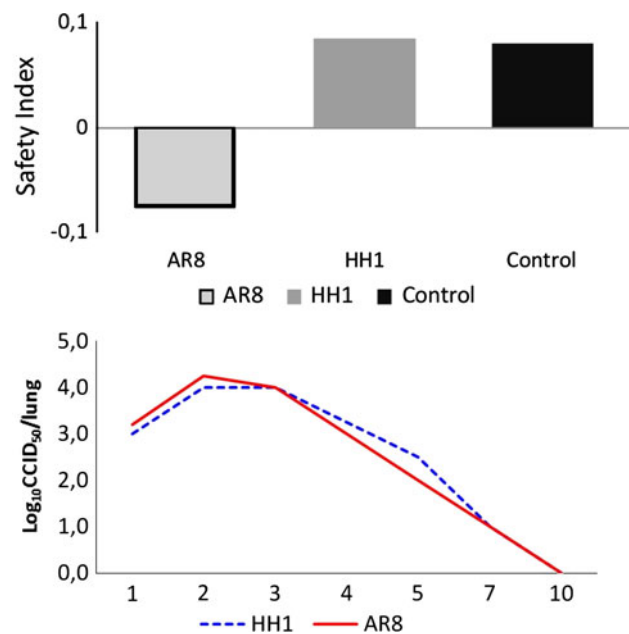
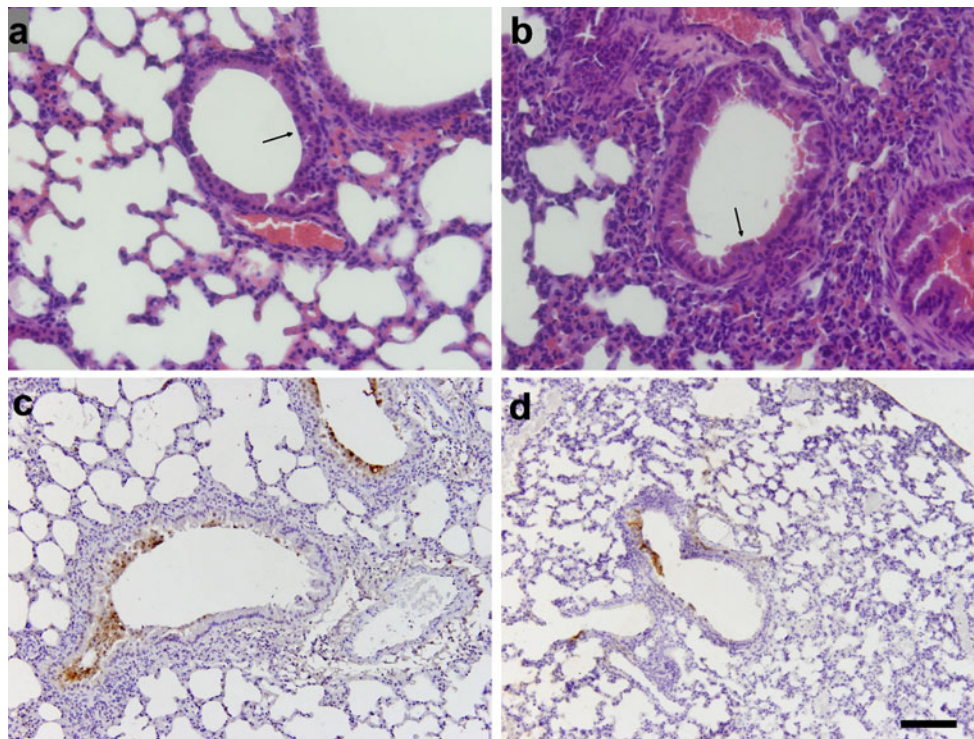


Fig. 1 a. Safety index, determined as the surface under the relative weight curve for the first 10 days after infection, calculated from AR8- and HH1-inoculated mice and control mice. **b.** Time-dependent patterns of virus isolation from lungs of AR8- and HH1-inoculated mice

Table 1 Immunohistochemistry (IHC) and screening of EHV-1 strains in lungs, liver, spleen and plasma, using viral isolation (VI) and PCR at different times post- inoculation (pi)

AR8 strain												
Group (day pi)	IHC			PCR				VI				
	Lung	Liver	Spleen	Lung	Liver	Spleen	Plasma	Lung	Liver	Spleen	Plasma	
1	X	–	–	X	X	X	X	X	X	X	X	
2	X	–	–	X	X	–	–	X	X	X	–	
3	X	–	–	X	–	–	–	X	–	–	–	
4	X	–	–	X	–	–	–	X	–	–	–	
7	–	–	–	–	–	–	–	–	–	–	–	
10	–	–	–	–	–	–	–	–	–	–	–	
HH1 strain												
Group (day pi)	IHC			PCR				VI				
	Lung	Liver	Spleen	Lung	Liver	Spleen	Plasma	Lung	Liver	Spleen	Plasma	
1	X	–	–	X	X	X	X	X	X	X	X	
2	X	–	–	X	X	X	X	X	X	X	X	
3	X	–	–	X	–	X	–	X	–	X	–	
4	X	–	–	X	–	–	–	X	–	–	–	
7	–	–	–	–	–	–	–	–	–	–	–	
10	–	–	–	–	–	–	–	–	–	–	–	

(–) negative; (x) positive

**Fig. 2** Histopathology of lungs from animals inoculated with the AR8 (a) or HH1 strain (b) on day 1 pi. Infection foci in the bronchiolar epithelium and moderate mononuclear infiltration around airways and vessels are shown. Detachment of the bronchial and

bronchiolar epithelium, indicative of infection with EHV-1 is indicated by an arrow. Immunohistochemical labeling of EHV-1 antigen in bronchiolar epithelial cells from animals inoculated with the AR8 (c) or HH1 strains (d) on day 2 pi is shown

airways and blood vessels were observed (Fig. 2a, b). Detection of EHV-1 antigen for both strains was positive only in the lungs from day 1 to day 7 pi (Fig. 2c, d).

In previous studies, we have shown that the AR8 strain is not grouped with HH1 due to differences in the intergenic region located between ORF 62 and ORF 63 [15]. This difference may alter the pathogenicity or at least be one factor that may affect viral behavior [9]. In the present work, we observed no significant changes in the average weight gain for each group. The safety index for the HH1 strain was significantly higher than that for AR8. This suggests lower pathogenicity of the HH1 strain at the titer and dose used in the present study. However, the HH1 strain produced a longer viremic phase than AR8. Since the number of viral particles used for inoculation was similar for each strain, this result may indicate a higher potential pathogenicity of the HH1 strain at the dose and titer used. Thus, the criterion used to define the pathogenic potential of a strain should be always clarified when making comparisons.

The histological and immunohistochemical findings for both strains were less evident than those reported by Awan et al. [2], Bartels et al. [3], Walker et al. [22, 23], and Yu et al. [25], who used other EHV-1 strains and at earlier time points pi. We suggest that variations in the viral infection dose and titer [22], differences in viral tissue tropism, the type of the anesthetic used for the inoculation [4], or host-specific factors may explain the heterogeneity between the results reported in the present work and those reported previously [6, 10, 11, 14].

The lack of lesions or positive immunohistochemical staining for EHV-1 antigens in the liver and spleen, together with the positive isolation of virus particles and DNA detection, may indicate that infected immune cells reached these organs while circulating. Although viral replication in the liver and spleen as a result of a systemic infection is not frequent, it has been reported in aborted equine fetuses and foals [12, 17] and, less commonly, in adult horses. In a case of disseminated infection in a two-year-old filly, histopathological lesions were found in the liver, spleen, adrenal glands and lungs and confirmed by IHC [8].

Further understanding of the kinetics, virulence and pathogenicity of the AR8 strain may support its use as a reference strain in the murine model. The results reported here for the AR8 and HH1 strains showed high agreement among the different technical methods for their evaluation, as has also been reported for horses [19]. However, we emphasize the importance of standardizing any EHV-1 strain selected to reproduce and compare the disease in the murine model before extrapolating results or drawing general conclusions.

Acknowledgments This study was supported by PICT 2011-1123 (FONCYT) and grants from CIC PBA, the Department for Science

and Technology of the National University of La Plata (SeCyT), and the National Academy of Agronomy and Veterinary (ANAV), Argentina. We thank Rosa Villegas, Guadalupe Guidi and Claudio A. Leguizamón for their technical support.

References

1. Alber DG, Greensill J, Killington RA, Stokes A (1995) Role of T-cells, virus neutralising antibodies and complement-mediated antibody lysis in the immune response against equine herpesvirus type-1 (EHV-1) infection of C3H (H-2k) and BALB/c (H-2d) mice. *Res Vet Sci* 59:205–213
2. Awan AR, Chong YC, Field HJ (1990) The pathogenesis of equine herpesvirus type 1 in the mouse: a new model for studying host responses to the infection. *J Gen Virol* 71:1131–1140
3. Bartels T, Steinbach F, Hahn H, Ludwig H, Borchers K (1998) In situ study of the pathogenesis and immune reaction of equine herpesvirus type 1 (EHV-1) infections on mice. *Immunol* 93:329–334
4. Eöry ML, Zanuzzi CN, Fuentealba NA, Sguazza GH, Gimeno EJ, Galosi CM, Barbeito CG (2013) Effects of different anesthetics in the murine model of EHV-1 infection. *Vet Pathol*. doi:10.1177/0300985813476062
5. Galosi CM, Vila Roza MV, Oliva GA, Pecoraro MR, Echeverría MG, Corva S, Etcheverrigaray ME (2001) A polymerase chain reaction for detection of equine herpesvirus-1 in routine diagnostic submissions of tissues from aborted foetuses. *J Vet Med B Infect Dis Vet Public Health* 48:341–346
6. Galosi CM, Barbeito CG, Vila Roza MV, Cid de la Paz V, Ayala MA, Corva SG, Etcheverrigaray ME, Gimeno EJ (2004) Argentine strain of equine herpesvirus 1 isolated from aborted foetus shows low virulence. *Vet Microbiol* 103:1–12
7. Gostzonyi G, Borchers K, Ludwig H (2009) Pathogenesis of equine herpesvirus- infection in the mouse model. *J Virol* 82:10820–10831
8. Hamir AN, Vaala W, Heyer G, Moser G (1994) Disseminated equine herpesvirus-1 infection in a two-year-old filly. *J Vet Diagn Invest* 6:493–496
9. Ibrahim el-SM, Pagmajav O, Yamaguchi T, Matsumura T, Fukushi H (2004) Growth and virulence alterations of equine herpesvirus 1 by insertion of a green fluorescent protein gene in the intergenic region between ORFs 62 and 63. *Microbiol Immunol* 48:831–842
10. Inazu M, Tsuha O, Kirisawa R, Kawakami Y, Iwai H (1993) Equid herpesvirus 1 infection in mice. *J Vet Med Sci* 55:119–121
11. Iwai H, Kodera A, Noriyuki S, Nakamura A (1998) Effect of equid herpesvirus 1 infection on parturition of mice. *J Equine Sci* 9:25–27
12. Jönsson L, Beck-Friis J, Renström LH, Nikkilä T, Thebo P, Sundquist B (1989) Equine herpes virus 1 (EHV-1) in liver, spleen, and lung as demonstrated by immunohistology and electron microscopy. *Acta Vet Scand* 30:141–146
13. Kawakami Y, Tokui T, Nakano K, Kum T, Hiramune T, Murase N (1970) An outbreak of abortion due to equine rhinopneumonitis virus among mares in the Hidaka district, Hokkaido. I. Epizootiological survey and virus isolation. *Bull Natl Inst Hlth* 61:9–16
14. Martín Ocampos GP (2010) Estudios moleculares-evolutivos y de virulencia en herpesvirus potencialmente abortogénicos para el equino. Tesis de Doctorado en Ciencias Naturales. Facultad de Ciencias Naturales y Museo, Universidad Nacional de La Plata
15. Martín Ocampos GP, Barbeito CG, Galosi CM (2011) Genomic studies and genetic characterization of equid herpesvirus type 1 (EHV-1) strains: estimating the global similarity by distance methods. *Int Res J Microbiol* 2:079–084

16. Mori CM, Mori E, Favaro LL, Santos CR, Lara MC, Villalobos EM, Cunha EM, Brandao PE, Richtzenhain LJ, Maiorka PC (2012) Equid herpesvirus type-1 exhibits neurotropism and neurovirulence in a mouse model. *J Comp Pathol* 146:202–210
17. Mukaiya R, Kimura T, Ochiai K, Wada R, Umemura T (2000) Demonstration of equine herpesvirus-1 gene expression in the placental trophoblasts of naturally aborted equine fetuses. *J Comp Pathol* 123:119–125
18. Reed LJ, Muench H (1938) A simple method of estimating fifty per cent end points. *The Am J Hyg* 27:493–497
19. Rimstad E, Evensen O (1993) The identification of equid herpesvirus 1 in paraffin-embedded tissues from aborted fetuses by polymerase chain reaction and immunohistochemistry. *J Vet Diagn Invest* 5:174–183
20. Smith PM, Zhang Y, Jennings SR, O'Callaghan DJ (1998) Characterization of the cytolytic T-lymphocyte response to a candidate vaccine strain of equine herpesvirus 1 in CBA mice. *J Virol* 72:5366–5372
21. van Woensel PA, Goovaerts D, Markx D, Visser N (1995) A mouse model for testing the pathogenicity of equine herpes virus-1 strains. *J Virol Method* 54:39–49
22. Walker C, Packiarajah P, Gilkerson JR, Love DN, Whalley JM (1998) Primary and challenge infection of mice with equine herpesvirus 1, strain HV25A. *Virus Res* 57:151–162
23. Walker C, Love DN, Whalley JM (1999) Comparison of the pathogenesis of acute equine herpesvirus 1 (EHV-1) infection in the horse and the mouse model: a review. *Vet Microbiol* 68:3–13
24. Whalley JM, Love DN (1995) Equine herpesvirus 1 HVS25A isolated from an aborted foetus produces disease in BALB/c mice. *Aust Vet J* 72:68–69
25. Yu MH, Kasem SG, Tsujimura K, Matsumura T, Yanai T, Yamaguchi T, Ohya K, Fukushi H (2010) Diverse pathogenicity of equine herpesvirus 1 (EHV-1) isolates in CBA mouse model. *J Vet Med Sci* 72:301–306