

Calbindin D28k Expression and the Absence of Apoptosis in the Cerebellum of *Solanum bonariense* L-Intoxicated Bovines

Veterinary Pathology
47(3) 569-572
© The American College of
Veterinary Pathologists 2010
Reprints and permission:
sagepub.com/journalsPermissions.nav
DOI: 10.1177/0300985809358040
http://vet.sagepub.com



J. M. Verdes¹, J. A. Moraña¹, D. Battes¹, F. Gutiérrez¹, F. Guerrero²,
A. Goicoa², L. E. Fidalgo², C. G. Barbeito³, C. N. Zanuzzi³,
E. L. Portiansky³, and E. J. Gimeno³

Abstract

Solanum bonariense intoxication is characterized by cerebellar neuronal vacuolation, degeneration, and necrosis. Cerebellar Purkinje cells seem especially susceptible, but more research is needed to determine the pathogenesis of neuronal necrosis and the mechanism of Purkinje cell susceptibility. Calbindin D28k (CbD28k) is highly expressed in Purkinje cells and has been used as a marker for normal and degenerative Purkinje cells. The goal of this study was to describe *S bonariense*-induced disease by ascertaining Purkinje cell-specific degenerative changes using CbD28k expression and to correlate this with apoptosis in Purkinje cells, as determined using TUNEL (transferase-mediated dUTP-biotin nick end-labeling) and ultrastructural changes. In all cases, an increase in both dose and duration of *S bonariense* intoxication resulted in a decrease in the number of Purkinje cells. CbD28k immunohistochemistry was an excellent marker for Purkinje cells because immunoreactivity did not change in normal or degenerative tissues. This finding suggests that excessive calcium excitatory stimulation does not induce rapid neuronal degeneration and death. As found in previous studies, TUNEL tests and electron microscopy suggest that Purkinje cell degeneration and death are not occurring via an apoptotic process. These findings suggest that *S bonariense* poisoning induces progressive Purkinje cell death that is not mediated by excitotoxicity or apoptotic activation.

Keywords

apoptosis, calbindin D28k, cattle, cerebellar degeneration, excitotoxicity, plant poisoning, Purkinje cells

Cattle eating *Solanum bonariense* (*S bonariense*) in western Uruguay developed periodic episodes of ataxia, hypermetria, hyperesthesia, head and thoracic limb extension, opisthotonos, nystagmus, and fall to the side or backward.¹⁴ Reported histological lesions include Purkinje cell vacuolation, degeneration, and necrosis. Similar cerebellar cortical degeneration has been described in other countries in which cattle were poisoned with different solanaceae species.^{7,12,13} Little is known of the degenerative mechanism, although the lack of apoptotic markers in degenerative neurons in *Solanum kwebense*-intoxicated cattle suggests that apoptosis is not involved.¹³

Neuronal calcium may play a role in neuronal survival as well as in apoptosis, pathological neuronal, degeneration and necrosis.⁶ Sustained increases in intracellular calcium levels, such as those observed after excitatory amino acid treatment or attributed to reduced transport activity, have been shown to correlate with increased protein and lipid degradation, which progresses to cell death.¹

In the cerebellum, where rapid firing neurons experience high levels of calcium influx, controlled calcium regulation is essential to avoid rapid neuronal death owing to excessive excitatory stimulation.¹ Intracellular calcium is mainly regulated by

calcium binding proteins (CaBPs). Interaction of calcium with these proteins represents one of the mechanisms by which a second messenger controls many biological processes.¹

Calbindin D28k (CbD28k) is a CaBP highly expressed in Purkinje cells. Recent work suggests that CbD28k is a marker of Purkinje cells in normal and degenerative cerebellar tissue.^{4,5} Researchers have speculated that in Purkinje cells, CbD28k expression is neuroprotective against degeneration in a variety of acute and chronic disorders.^{1,2}

¹ Departments of Molecular and Cellular Biology (Biophysics) and Pathology, School of Veterinary, Universidad de la República, Montevideo, Uruguay

² Department of Anatomy and Animal Production, Veterinary Clinical Sciences, School of Veterinary, Universidad de Santiago de Compostela, Lugo, Spain

³ Institute of Pathology, School of Veterinary Sciences, National University of La Plata, La Plata, Argentina

Corresponding Author:

Dr José Manuel Verdes, Department of Molecular and Cellular Biology (Biophysics), School of Veterinary, Universidad de la República, Av. A. Lasplacas 1550, CP 11600, Montevideo, Uruguay
Email: jmverdes@fvvet.edu.uy

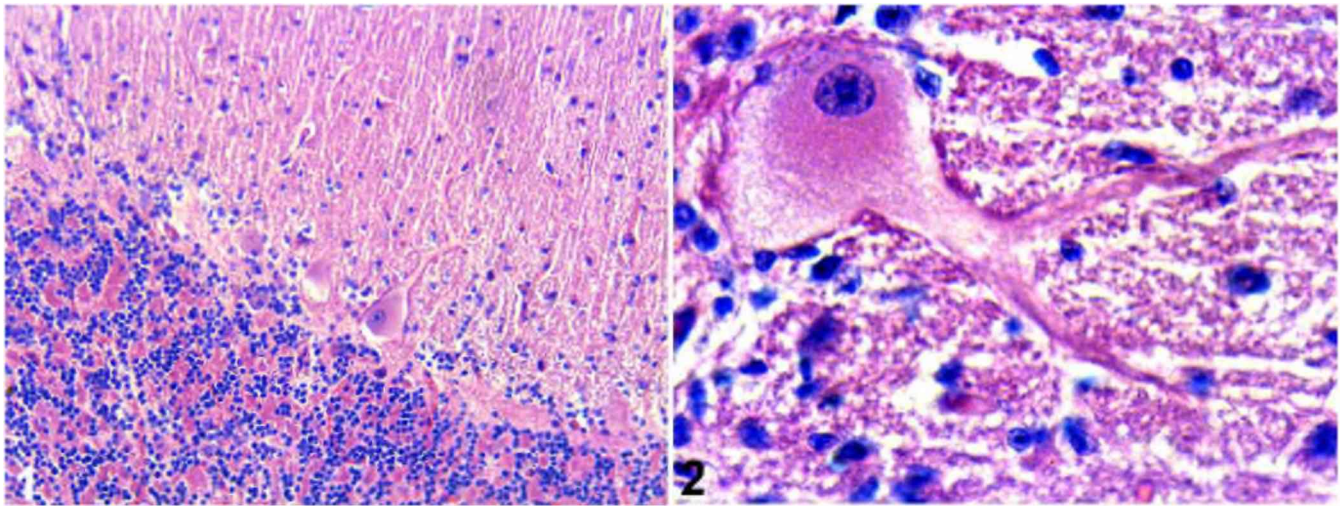


Figure 1. Cerebellar cortex of spontaneously poisoned heifer showing lower Purkinje cell density per unit length. HE. **Figure 2.** Purkinje neuron from experimentally poisoned steer showing vesiculated perikaryon and nuclear displacement. HE.

The goals of the present work were to describe the effects of *S bonariense* in cattle by monitoring Purkinje cell populations using CbD28k expression. Labeled cells were also evaluated for evidence of apoptosis using the TUNEL (transferase-mediated dUTP-biotin nick end-labeling) test and ultrastructural evaluation.

Study details regarding plant description and experimental methodology have been reported.¹⁴ Two control steers, 2 heifers naturally poisoned with *S bonariense*, and 4 steers experimentally intoxicated with *S bonariense* were prepared and examined. In the experimental portion of the study, each of the 4 experimentally intoxicated steers received *S bonariense* at varying doses and durations to produce different degrees of cerebellar degeneration. Steer No. 1 received 0.512 kg of fresh leaves of *S bonariense* per kilogram body mass (kg BM) during 61 days (0.50 times the cerebellar sign-inducing threshold [CSIT] dose); steer No. 2, 1.024 kg plant per kg BM for 128 days (1.00 times CSIT dose); steer No. 3, 1.28 kg plant per kg BM for 160 days (1.25 times CSIT dose); and steer No. 4, 2.048 kg plant per kg BM for 198 days (2.00 times CSIT dose).

Slices from 6 selected areas of the cerebellum of all animals in the study (3 from the cranial, medial, and caudal areas of the vermis; 1 from each lateral hemisphere; and 1 from the flocculus) were formalin fixed, paraffin embedded, and sectioned at 5 μ m. One slice from each location was stained with hematoxylin and eosin for histological observation. Immunohistochemistry of the remaining slices was performed using a mouse monoclonal primary antibody, anti-CbD28k (clone NLC, Novocastra, Newcastle Upon Tyne, UK). Briefly, slices were incubated with primary antibody overnight. Following 3 washings of the slides with phosphate buffered saline, samples were incubated with a peroxidase-labeled polymer system (EnVision Universal Peroxidase, DakoCytomation, Glostrup, Denmark) for 45 minutes. Diaminobenzidine was used as a chromogen.

Immunohistochemically stained slides were counterstained with Mayer's hematoxylin.

Evaluation for possible apoptosis in degenerative Purkinje cells was performed using the in situ TUNEL apoptosis test (kit ApoTag, Chemicon, Temecula, CA) following the manufacturer's suggested protocol on additional serial cerebellar sections from these animals. All TUNEL-labeled samples were counterstained with methylene green. The TUNEL protocol included positive controls obtained from samples of bovine small intestine and a negative control obtained by excluding the terminal deoxynucleotidyl transferase step of the original method.

For transmission electron microscopy (TEM) evaluation, 1-mm³ duplicate tissue block samples from each cerebellum were fixed in cacodylate-buffered 4% glutaraldehyde, postfixed in 1.5% osmium tetroxide, dehydrated via alcohols and propylene oxide, and embedded in epon. Semithin and thin sections were stained with 1% toluidine blue and uranyl acetate/lead citrate, respectively.¹⁰

Each cerebellar sample was subjectively compared, and the histological studies confirmed the loss of Purkinje cells in natural and experimentally intoxicated animals (Figs. 1, 2). With a subjective evaluation, the loss of Purkinje cells in this study was similar to that of previous studies that reported degeneration or loss of Purkinje cells.^{8,9,14}

CbD28k immunoreactivity was always intense and regular in Purkinje cells from all sections of the cerebellum in control animals as well as animals experimentally and naturally poisoned. CbD28k immunoreactive intensity was observed in Purkinje cell bodies, axons, and dendrites and was similar in controls as well as experimentally poisoned and naturally poisoned animals (Figs. 3, 4). Degenerative axons or spheroids in the cerebellar white matter were also CbD28k positive. In all analyzed animals, neurons of the deep cerebellar nuclei were negative for CbD28k, whereas the surrounding synaptic terminals were positive (Fig. 4, lower inset).

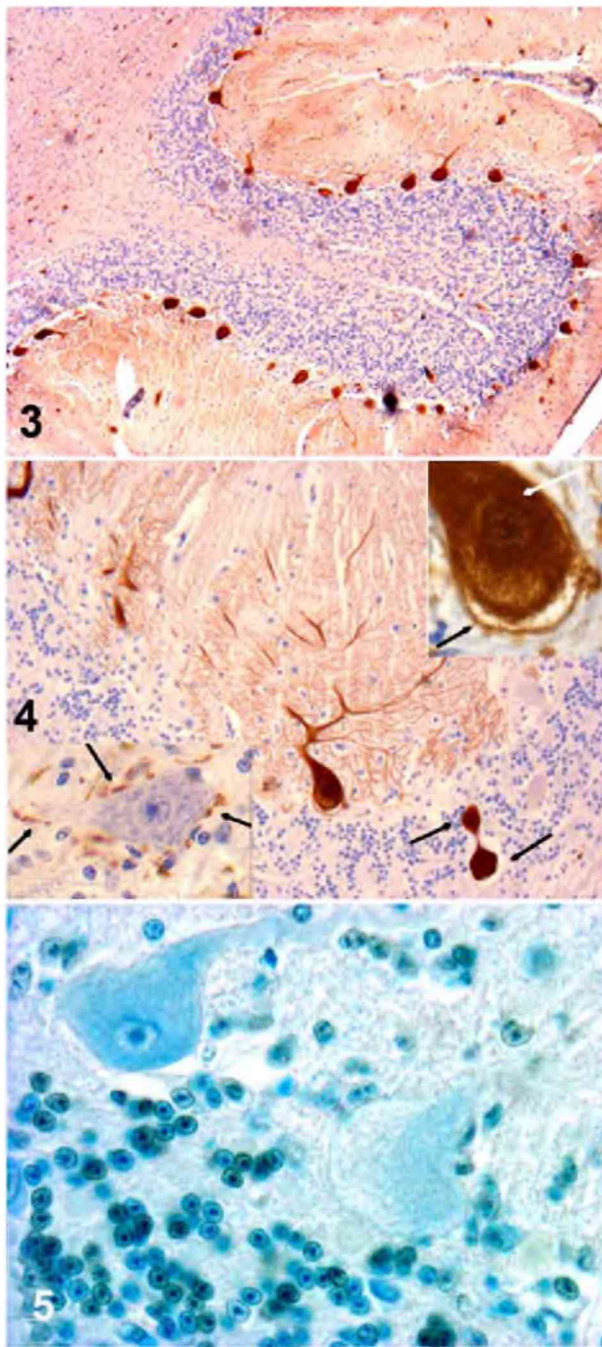


Figure 3. Calbindin D28k immunoreactivity of cerebellar folia in a spontaneously poisoned heifer showing brown stained Purkinje cells and their dendritic processes. **Figure 4.** A CbD28k-immunoreactive Purkinje neuron of the same organ and its dendritic processes showing a neighboring axon (possibly from another Purkinje cell) with 2 positive axonal spheroids in the granular layer (arrows). In upper inset, a higher magnification of the Purkinje cell easily distinguishes a vesiculated perikaryon (black arrow) and nuclear displacement (white arrow). In lower inset, neurons in the cerebellar nuclei were immunohistochemically negative against CbD28k; nevertheless, surrounding synaptic projections from Purkinje neurons appeared strongly positive (arrows). **Figure 5.** Purkinje cells from experimental poisoned steer showing negative reaction against TUNEL test.

Populations of Purkinje cells from equivalent cerebellar areas in intoxicated and control bovines showed no positive reaction to TUNEL apoptotic reagents despite obvious progressive Purkinje cell loss (Fig. 5). This finding was supported by TEM, which showed an absence of apoptotic figures in spite of signs of Purkinje cellular damage (data not shown).

The present study confirms a loss of Purkinje cells in *S bonariense* intoxication. Similar Purkinje cell loss has been observed after intoxication by other solanaceae species.^{7,12-14} In advanced cases, the progressive disappearance of dendritic processes from degenerative Purkinje cells results in a corresponding thinning of the molecular layer.⁹ This study demonstrated that longer intoxication times resulted in correspondingly fewer Purkinje cells in the cerebellar laminae of all experimentally intoxicated steers, confirming the progressive disappearance of Purkinje neurons and their process.

As with other species, we found that CbD28k expression is high in bovine Purkinje cells. Purkinje cells have intense CbD28k immunoreactivity, which appears to be independent of the degree of cerebellar degeneration. Although similar findings have been reported,⁸ Haworth et al⁴ and Ishikawa et al⁵ reported a significant decay in CbD28k immunoreactivity in other neurodegenerative models. Differences between these studies may be due to the dependence of CbD28k immunoreactivity on the degenerative process. For example, some excitotoxic degenerative Purkinje cells may have disruption of the calcium-buffering system. CbD28k plays a protective role against calcium-mediated excitatory amino acid neurotoxicity by reducing the levels of intracellular free calcium.⁵ Disruption of the calcium-buffering system may result in CbD28k depletion and loss of immunoreactivity. This does not seem to be the case in *S bonariense* poisoning.

The negative reaction observed in samples where the TUNEL test was applied indicates that Purkinje cells do not die by apoptosis. Van der Lugt et al¹³ reached a similar conclusion for bovines intoxicated with *Solanum kwebense*. We confirmed these findings using TEM, which showed the absence of typical apoptotic signs in the nucleus of affected Purkinje cells. Results suggest that the changes observed in degenerative neurons are more indicative of necrosis, although this hypothesis must be confirmed by other methods.

Neurons in cerebellar nuclei were negative for CbD28k antibody, but the surrounding Purkinje cell axonal projections were strongly positive. The same pattern of immunoreactivity was described in primates and rats^{1,3,11,15} and is probably due to specific expression of other CBPs that buffer calcium in these neurons (ie, calretinin or parvalbumin).^{1,3}

In summary, CbD28k antibodies appear to specifically react with bovine antigens, thereby suggesting an accurate marker for bovine Purkinje cells. The combination of CbD28k expression, lack of TUNEL staining, and reported TEM findings suggests that *S bonariense* poisoning induces progressive neuronal death that is not mediated by excitotoxicity or activation of apoptosis. Additional studies using neurodegenerative markers may be useful in characterizing the cerebellar lesions.

Acknowledgements

This work was supported by project No. FPR/F/BI/49/28 (SECTIP, Argentina; PDT-MEC, Uruguay) and CSIC-UdelaR (Uruguay). C.G.B., C.N.Z., E.L.P., and E.J.G. are members of CONICET, Argentina. We thank Dr B. Stegelmeier (Poisonous Plants Research Laboratory, US Department of Agriculture, Logan, Utah) for his constructive criticism and proofreading. Our gratitude to Alba Román and Rosa Villegas for their technical assistance.

Declaration of Conflicting Interests

The authors declared that they had no conflicts of interest with respect to their authorship or the publication of this article.

Financial Disclosure/Funding

The authors declared that they received no financial support for their research and/or authorship of this article.

References

- Bastianelli E: Distribution of calcium-binding proteins in the cerebellum. *Cerebellum* **2**:242–262, 2002.
- Clowry GJ, McHanwell S: Brainstem motor nuclei respond differentially to degenerative disease in the mutant mouse wobbler. *Neuropathol Appl Neurobiol* **30**:148–160, 2004.
- Fortin M, Marchand R, Parent A: Calcium-binding proteins in primate cerebellum. *Neurosci Res* **30**:155–168, 1998.
- Haworth R, McCormack N, Selway S, Pilling AM, Williams TC: Calbindin D-28 and microtubule-associated protein-2: their use as sensitive immunohistochemical markers of cerebellar neurotoxicity in a regulatory toxicity study. *Exp Toxicol Pathol* **57**:419–426, 2006.
- Ishikawa K, Mizusawa H, Fujita T, Ohkoshi N, Doi M, Komatsuzaki Y, Iwamoto H, Ogata T, Shoji S: Calbindin-D 28k immunoreactivity in the cerebellum of spinocerebellar degeneration. *J Neurol Sci* **129**:179–185, 1995.
- Krebs J: The role of calcium in apoptosis. *Biometals* **11**:375–382, 1998.
- Menzies JS, Bridges CH, Bayley EM: A neurological disease of cattle associated with *Solanum dimidiatum*. *Southwest Vet* **32**:45–49, 1979.
- Park E, McKnight S, Ai J, Baker AJ: Purkinje cell vulnerability to mild and severe forebrain head trauma. *J Neuropathol Exp Neurol* **65**:226–234, 2006.
- Rech RR, Rissi DR, Rodrigues A, Pierezan F, Piazer JVM, Kommers GD, Barros CSL: Intoxicacao por *Solanum fastigiatum* (solanaceae) em bovinos: epidemiologia, sinais clínicos e morfometria das lesões cerebelares. *Pesq Vet Bras* **26**:183–189, 2006.
- Reynolds ES: The use of lead citrate at high pH as an electron opaque stain in electron microscopy. *J Cell Biol* **17**:208–212, 1963.
- Rickmann M, Wolff JR: S100 protein expression in subpopulations of neurons of rat brain. *Neuroscience* **67**:977–991, 1995.
- Riet-Correa F, Mendez MC, Schild AL, Summers BA, Oliveira JA: Intoxication by *Solanum fastigiatum* var. *fastigiatum* as a cause of cerebellar degeneration in cattle. *Cornell Vet* **73**:240–256, 1983.
- van der Lugt JJ, Bastianello SS, van Ederen AM, van Wilpe E: Cerebellar cortical degeneration in cattle caused by *Solanum kwebense*. *Vet J*, in press.
- Verdes JM, Moraña A, Gutiérrez F, Battes D, Fidalgo LE, Guerrero F: Cerebellar degeneration in cattle grazing *Solanum bonariense* (“Naranjillo”) in western Uruguay. *J Vet Diagn Invest* **18**:299–303, 2006.
- Yew DT, Luo CB, Heizmann CW, Chan WY: Differential expression of calretinin, calbindin D28K and parvalbumin in the developing human cerebellum. *Brain Res Dev Brain Res* **103**:37–45, 1997.