



Case Report

Lesions of hypertrophic osteopathy in the forelimbs of a dog associated with pulmonary metastasis from a periosteal osteosarcoma

Andrea V. Pachamé¹, Marcos J. Beltrán², Nestor E. Recchiuti³, Enrique L. Portiansky^{1,4}, Adriana R. Massone⁵, Eduardo J. Gimeno^{1,5*}

¹Chair of General Pathology - Facultad de Ciencias Veterinarias, Universidad Nacional de La Plata, La Plata, Argentina.

²Chair of Complimentary Diagnostic Methods, Area Radiology - Facultad de Ciencias Veterinarias, Universidad Nacional de La Plata, La Plata, Argentina.

³Private activity.

⁴Image Analysis Laboratory - Facultad de Ciencias Veterinarias, Universidad Nacional de La Plata, La Plata, Argentina.

⁵Special Pathology Laboratory "Dr. Bernardo Epstein" - Facultad de Ciencias Veterinarias, Universidad Nacional de La Plata, La Plata, Argentina.

Corresponding Author: Facultad de Ciencias Veterinarias, Universidad Nacional de La Plata, Calles 60 y 118, (1900), La Plata, Argentina.

E-mail: ejgimeno@gmail.com

Submitted December 20th 2016, Accepted March 23rd 2017

Abstract

Hypertrophic osteopathy is commonly associated with primary lung neoplasms. It may also be secondary to intrathoracic lesions such as pulmonary metastasis, granulomatous pleurisy and chronic pneumonia, among others. It is characterized by progressive proliferation of sub periosteal bone tissue in limb bones. Clinically, patient usually exhibits lameness. It is a rare disease most frequently observed in dogs among domestic animals. A case of a dog with pulmonary hypertrophic osteopathy associated with pulmonary metastases coming from an appendicular periosteal osteosarcoma is reported.

Key words: hypertrophic osteopathy, metastasis, periosteal osteosarcoma, canine.

Introduction

Hypertrophic osteopathy, also known as pulmonary hypertrophic osteopathy (PHO) is a rare, progressive and diffuse disease characterized by proliferation of periosteal bone tissue along the diaphysis and metaphysis of large limb bones (1, 2, 4, 11). Dogs are considered the pets with greater predisposition to this disease (4). In these animals, the most common trigger of PHO is the primary or metastatic lung neoplasia (1, 10). PHO incidence is much higher in some types of thoracic lesions than in others. Thus, dogs with osteosarcoma (OSA) pulmonary metastases are more likely to develop the disease than those with pulmonary metastases from carcinomas (4, 5). It has also been described that PHO may be associated with other chronic pulmonary processes such

as pulmonary tuberculosis, lung abscesses, chronic bronchitis, and with *Dirofilaria immitis* infections (12). Unlike humans, there is no joint involvement in animal cases. Therefore, the term PHO is preferred to hypertrophic osteoarthropathy (3).

Although there is no defined racial predisposition, Boxer breed dogs and other large breeds are more often affected (5). Older dogs (from 8.5 years old) have greater tendency to develop PHO as compared to younger animals (5). Although the cause is varied the pathogenesis is not well understood (3). Although several theories are trying to define it none of them was fully demonstrated. One of the widely-accepted theories considers that PHO occurs due to a neurovascular reflex mechanism. This autonomic reflex would be mediated by the afferent branches of the vagus or intercostal nerves and would produce a rapid increase in

peripheral blood flow. Peripheral vasodilation results in a characteristic periosteal proliferation (3, 9).

A case of a dog with PHO associated with pulmonary metastases coming from an appendicular periosteal osteosarcoma is reported.

Case report

A 9 years old half-blood neutered male dog was received in a private veterinary clinic of La Plata, province of Buenos Aires, Argentina. For several days, the animal did not eat and showed claudication of thoracic limbs. In the last 24 hours, the animal adopted sternal recumbence, with total inability to stand up and showing severe manifestations of pain. Anamnesis indicated that two years ago, the patient was diagnosed as having periosteal OSA in the distal portion of the right hind limb. At that time, a high limb amputation was performed. The patient continued its recovery with a chemotherapy drugs based treatment.

Considering the described background, the dog was clinically examined and x-rays were taken (Fig. 1). The animal rested all the time in sternal decubitus with total inability to stand up and poor general condition. Clinical examination collected the following data: rectal temperature was 39°C; heart rate was 120 beats per minute; respiratory rate was 40 breaths per minute with intermittent wheezing; the capillary refill lasted for 2 seconds and the conjunctival mucosa was slightly hyperemic. Although cardiac auscultation expressed no alterations pulmonary thoracic auscultation revealed the presence of crepitus in the right hemithorax. The remaining lung field had no peculiarities. Abdominal palpation revealed no abnormal data. Thoracic limbs were thickened, without edema, with swelling and induration areas of soft tissue, mainly affecting the metacarpals and distal epiphysis of the radius and ulna.

Radiological examination of the thoracic limbs showed a periosteal reaction from the metacarpals to the bone humerus. Periosteal reaction was solid, irregular and perpendicular to the cortex at the level of the first phalanx and metacarpal bone of the five fingers, as well as at the radius, ulna and distal caudal third of the humerus. Thoracic radiography revealed a mass image of about 8 x 4.5 cm in the middle region and in relation to the right cardiac silhouette (Fig. 1). The radiological diagnosis was consistent with a tumor mass.

As for the clinical observations, hematological studies were indicated. However, due to poor quality of life of the dog, the owners decided not to go ahead and proceeded with euthanasia, which was conducted according to ethical standards.

The owners did not give consent for necropsy, but allowed aspiration of thorax mass. The puncture was guided by ultrasound and the material was subsequently sent for cytological study. Cytology displayed marked

variation in cell size and shape. Cells contained scattered, pink cytoplasmic granules and vacuoles (Fig. 2).

Discussion

Hypertrophic osteopathy is a frequent disease of humans and animals, often associated with intrathoracic neoplasms, particularly with primary lung tumours and OSA metastases (3). However, it is a rare disease in routine small animal clinics (11).

In most cases, the correct clinical diagnosis of PHO could arise from a detailed medical history and from clinical and radiographic findings (6). Nevertheless, it is important to establish a differential diagnosis with bone tumours and hypertrophic osteodystrophy (11). Bone tumours have a unilateral presentation, unlike the bilateral presentation often occurring in PHO. On the other hand, hypertrophic osteodystrophy is an exclusive alteration of young animals while PHO is often detected in adult or elderly animals due to a progressive proliferation of subperiosteal bone tissue (11). Moreover, PHO cause injury to the four limbs without affecting the joints (7).

While the pathogenesis of PHO is not entirely clarified, neurogenic theory is widely accepted because in most cases there is a regression of bone lesions after vagotomy. It is proposed that intra- or extra-thoracic lesions compressing the nerve vagus originate impulses that initiate a reflex vasodilatation in the limbs, increasing blood flow and enabling deposition of fibrous tissue and bone (4, 5). This would indicate that the described skeletal abnormalities are the result of nerve reflective impulses arising from intrathoracic injuries (4, 5).

Hypertrophic osteopathy causes an increase of peripheral blood flow and periosteal proliferation throughout the length of the diaphysis of long bones, often beginning in the toes and extending proximally, reaching the bones femur and humerus (1, 8). At the beginning of the injuries, proliferation of soft tissue occurs, which then transforms into osteophytes which in turn tend to spread from the bone cortex, being responsible for the lameness observed in patients (8). Radiographs of the affected limbs usually show increased density of soft tissue, combined with an osteophyte reaction. This lesion is characterized by periosteal proliferation with a characteristic granular spicular or treelike appearance, which tends to spread from the bone cortex and angled 90° to the surface of the periosteum, without involvement of the cortical bone layer (11). Also, the thickening is usually bilateral however, there are no differences in the degree of bias in the forelimb compared to the hind limb. The pathogenesis described by other authors may explain the thickening of the limbs described in the present clinical report. It is important to note that in this case, lesions showed periosteal proliferation exclusively in the forelimb; hind limbs did not show injuries from the radiological point of view.

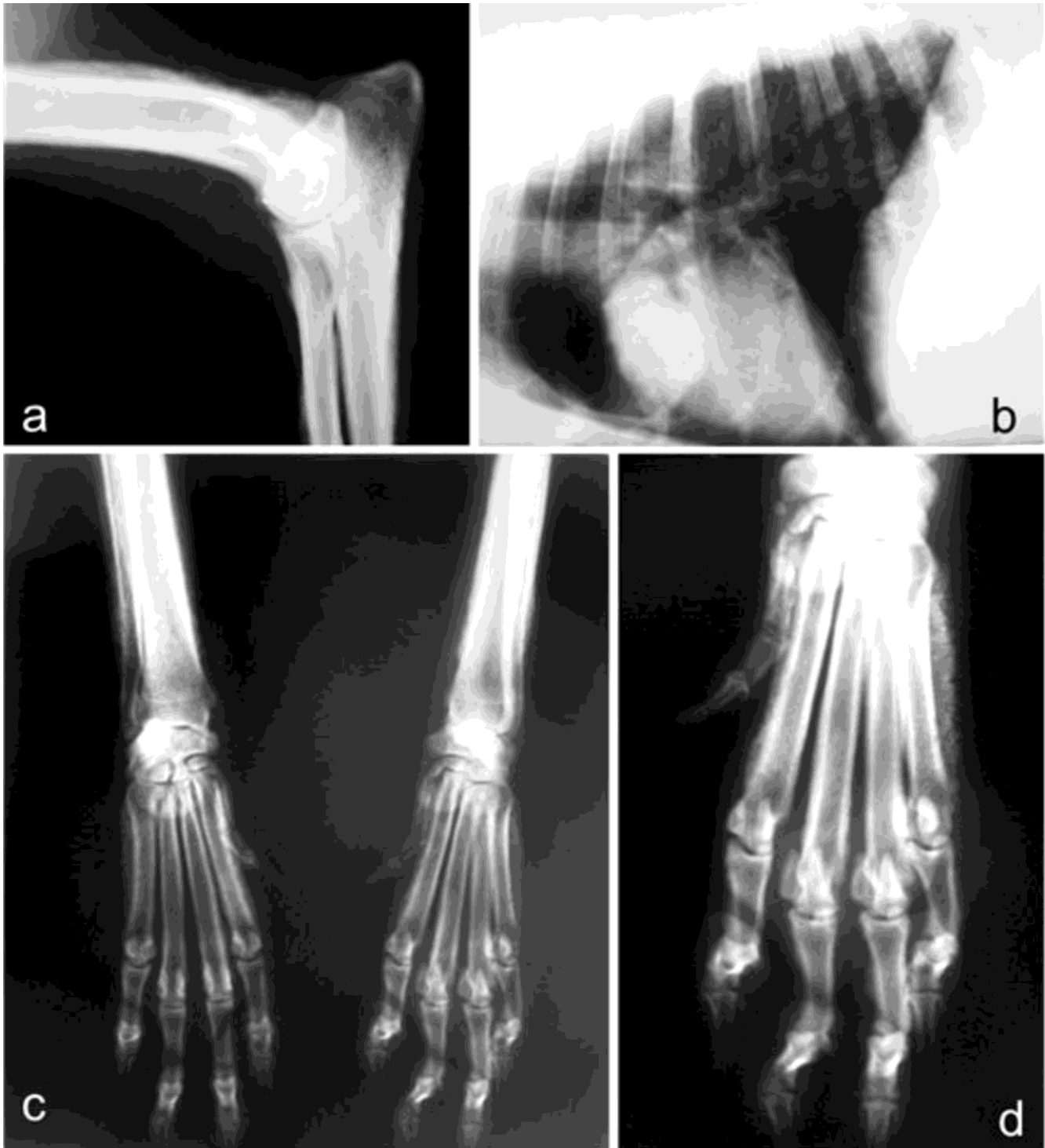


Figure 1. Pulmonary hypertrophic osteopathy. **(a)** Solid periosteal reaction, irregular and perpendicular to the cortex at the radius, ulna and distal caudal third of the humerus; **(b)** Thoracic radiography revealed a mass image located in the middle region and in relation to the right heart silhouette; **(c-d)** Solid periosteal reaction, irregular and perpendicular to the cortex at the first phalanx and metacarpal of the five finger.

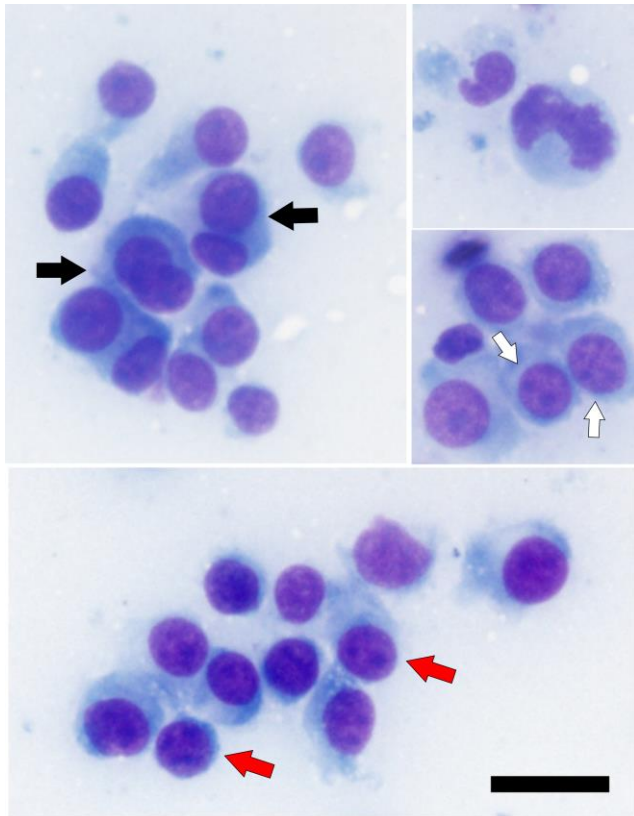


Figure 2. Cytology of a pulmonary metastasis from the periosteal osteosarcoma. Abundant cell clusters with marked variation in size and shape (from oval to slightly fusiform). Occasional binucleate cells (black arrows). Multiple evident nucleoli (white arrow) and anisonucleolus (red arrows). Cells contain scattered, pink cytoplasmic granules and vacuoles. Staining: May-Grünwald. Bar = 20 μ m.

In this report, PHO was associated with pulmonary metastases from a chronic course periosteal osteosarcoma. According Lenehan and Fetter (5) the frequency of PHO in dogs is much higher in cases with pulmonary metastases from OSA than those with lung metastasis secondary to other types of malignancies. In our case, the cause of PHO would be related to OSA metastasis in the lungs and the presence of this newly formed tissue would be related with the neurogenic theory postulated as the more accepted pathogenic mechanism in the canine species. Finally, it is noteworthy that the large size of the adult dog hereby reported is in coincidence with the experience described by Brodey (3).

It is well known that PHO is a consequence of a variety of lung lesions. In our case, PHO was due to pulmonary metastasis from a periosteal osteosarcoma, a rare association according to the literature (3).

Acknowledgements

This paper was supported by Project 11/V231, UNLP. The authors thank histotechnologists Carolina

Aralda and Lorena Díaz. ELP and EJJ are Research Career Member of the National Scientific Research Council (CONICET) of Argentina.

References

1. Allan GS. Signos radiográficos de las enfermedades articulares en perros y gatos. In: Thrall DE. Tratado de Diagnóstico Radiológico Veterinario. 5th ed. Buenos Aires: Inter-Médica Editorial; 2009. p. 325-66.
2. Bergman PJ. Paraneoplastic syndromes. In: Withrow SJ, Macewen EG, editors. Small animal clinical oncology. 4th ed. St Louis: Saunders Elsevier; 2007. p. 77-94.
3. Brodey RS. Hypertrophic osteoarthropathy in the dog: a clinicopathologic survey of 60 cases. J Am Vet Med Assoc. 1971;159:1242-56.
4. Craig LE, Dittmer KE, Thompson KG. Bone and joints. In: Maxie MG, editor. Jubb, Kennedy and Palmer's. Pathology of Domestic Animals. 6th ed. Philadelphia: Elsevier; 2016. p. 92-4.
5. Lenehan TM, Fetter AW. Hypertrophic osteopathy. In: Newton CD, Nunamaker DM, editors. Textbook of Small Animal Orthopaedics. Lippincott; 1985. p. 243-7. Available from: http://cal.vet.upenn.edu/projects/saortho/chapter_51/51mast.htm
6. Lindenbaum S, Alexander H. Infections stimulating bone tumors. A review of subacute osteomyelitis. Clin Orthop Relat Res. 1984;184:193-203.
7. Liptak JM, Monnet E, Dernell WS, Withrow SJ. Pulmonary metastatectomy in the management of four dogs with hypertrophic osteopathy. Vet Comp Oncol. 2004;1:1-12.
8. Ogilvie GK, Moore AS. Fiebre, Osteopatía Hipertrofica e Hiper cortisolismo. In: Manejo del paciente canino oncológico: Guía práctica para la atención compasiva. Inter-Médica Editorial; 2008. p. 405-8.
9. Pineda CJ, Lavin MM, Goobar JE, Sartoris DJ, Clopton P, Resnick D. Periostitis in hypertrophic osteoarthropathy: relationship to disease duration. Am J Roentgenol. 1987;148(4):773-8.
10. Ramoo S. Hypertrophic osteopathy associated with two pulmonary tumours and myocardial metastases in a dog: a case report. N Z Vet J. 2013;61(1):45-8.
11. Rodríguez F, Mayoral I, Muñoz FM, Rodríguez J, Sáinz A, Ynaraja E. Osteoartropatía hipertrófica pulmonar asociada a megaesófago en un perro. Clín Vet Peq Anim. 1995;15:71-6.
12. Wheeldon EB, Pirie HE, Fisher EW, Lee R. Chronic respiratory disease in the dog. J Small Anim Pract. 1977;18(4):229-46.