

NOTE

Dermocystidiosis induced by the parasite *Dermocystidium* sp. in the ornamental fish *Paracheiroidon axelrodi*

S. E. Plaul^{1,2*}, P. F. Andrés Laube^{1,2}, M. M. Montes^{3,4},
E. Topa³, S. R. Martorelli^{3,4} and C. G. Barbeito^{2,4}

¹*Servicio de Ictiopatología y Acuicultura, Facultad de Ciencias Veterinarias (FCV). Av. 60 y 118, Universidad Nacional de La Plata (UNLP). La Plata, Buenos Aires, Argentina;*

²*Laboratorio de Histología y Embriología Descriptiva, Experimental y Comparada, FCV, UNLP, Argentina;* ³*Centro de Estudios Parasitológicos y Vectores (CEPAVE), CCT-La Plata-CONICET-UNLP. Calle 122 e/ 61 y 62. La Plata, Buenos Aires, Argentina;* ⁴*CONICET*

Abstract

The Rio Negro floodplain (tributary of the Amazon River) is a natural habitat of the cardinal tetra *Paracheiroidon axelrodi*. In home aquaria, this species has high vulnerability to superficial infections and is affected by the protist *Dermocystidium*. Protist cysts were located in the dermis causing lesions reaching the epidermis. We observed that a few weeks after the introduction of new wild ornamental fish (mostly *Hemigrammus* sp. or *Hyphessobrycon* sp.) into established home aquaria, the cardinal tetra fish became infected, suggesting that the new fish could have acted as carriers.

The Amazon basin contains the world's highest diversity of freshwater fishes (Chao, 2001). In this habitat, the so-called "tetras" can be found; they are native small freshwater fishes belonging to the family Characidae. Many of these specimens are extremely popular for home aquaria, as they are brightly colored and easy to keep in captivity. More than 50 species from the Rio Negro floodplain (tributary of the Amazon River) are used as ornamental fish (Prang, 2007), but the cardinal tetra (*Paracheiroidon axelrodi* (Schultz, 1956)), constitutes more than 80% of the total catch (Chao, 2001; Zehev et al., 2015).

In Argentina *P. axelrodi* is the largely imported fish (34.33%), while *Paracheiroidon* sp. is the 4th in respect to fish export (Panné Huidobro, 2015). Most of the ornamental fish caught in wild environments are subject to injury during capture, placed in stressful conditions during transportation and are not quarantined for the proper amount of time to prevent the introduction of transmissible pathogens and the emergence of infectious diseases after they arrive at different pet shops to be sold (Doyle et al., 1996; Kim et al., 2002).

* Corresponding author's e-mail: splaul@fcnym.unlp.edu.ar




Figure 1. a) Lateral view of the infected fish *Paracheirodon axelrodi* with a macroscopic lesion showing white tubular cysts of *Dermocystidium* sp.; b) Fresh preparation under light microscope. Released spores of an epidermal cyst. Inset: tubular cyst of *Dermocystidium* sp.

Cases of parasitism of cardinal tetra occurring after the introduction of wild ornamental fish into established home aquaria have been reported to the Ichthyopathology and Aquaculture Department (*Servicio de Ictiopatología y Acuicultura, Facultad de Ciencias Veterinarias, Universidad Nacional de La Plata*). Two weeks after the introduction of the new fish, mostly specimens of *Hemigrammus* Gill or *Hyphessobrycon* Durbinand, a change in the behavior of cardinal tetras were observed. They began to lose colour, the skin appeared opaque; and fish were lethargic with sudden bursts of erratic swimming. After fifteen days, the cardinal tetra exhibit tubular cysts on the body surface. Throughout this period, no clinical signs were observed in the other species of the home aquaria.

Cysts were removed from the host surface and observed under a light microscope. Sterile cotton swabs were used on the affected areas to remove a sample for isolation and identification of the aetiological agent. Swabs were incubated employing heterotrophic plate count methods: the spread plate method (APHA, 1992) and alternative Ray's fluid thioglycollate medium (ARFTM) (Dungan and Bushek, 2015). In addition, ten *P. axelrodi* specimens affected with

varying numbers of cysts were studied; six males and four females, measuring 25.6 ± 0.62 mm of standard length. Fish were humanely euthanised by overdose of eugenol anaesthetic (30 mg L^{-1}) (García-Gómez et al., 2002) and the whole fish were fixed in 10% buffered formalin. Decalcification was performed by immersion in disodium EDTA CAS (6381-92-6) Biopack, Argentina (Plaul et al., 2017). After dehydration and paraffin embedding, the samples were sectioned at $5 \text{ }\mu\text{m}$, stained with hematoxylin and eosin (H&E), Masson's trichrome and PAS/hematoxylin and observed by light microscopy. Micrographs were taken with an Olympus microscope (model CX31) equipped with an Olympus camera (model U-CMAD3, Tokyo, Japan).

According to the morphology of the cysts and the structure of the spores, the aetiological agent was assigned to the genus *Dermocystidium* (Figure 1b). The employed culture media did not support its growth, but numerous environmental and commensal bacteria were isolated from the skin, mainly *Aeromonas* sp. and *Pseudomonas* sp.

Pathological analysis showed a macroscopic lesion characterised by a transparent tubulous

cyst resembling a nematode, measuring 2.6–3.4 mm (2.86 ± 0.31 mm) in length and 2.0–3.7 mm (2.86 ± 0.64 mm) in width. *Dermocystidium* sp. typically forms white tubular cysts (Figure 1a), in our case surrounded by a transparent oedema that protruded towards the surface. Histopathological analysis of skin showed that the tubular cyst contained a great quantity of spores of the same developmental stage. Spores were spherical, varying in size from 5.0 to 8.0 μm (7.0 ± 0.76 μm) in diameter, with a refractile inclusion 4.0–6.0 μm (4.94 ± 0.65 μm) in diameter, centrally or eccentrically situated. Cysts were located in the dermis and causing lesions extending to the epidermis and exerting pressure on the musculature as it increases in size (Figure 2a, b). The alterations in the skin were consistent with a chronic process. Haemorrhagic areas in dermis and muscle were observed, as well as mild vascular congestion. Around the cysts, an infiltration of numerous inflammatory cells, mainly lymphocytes and macrophages, was detected as part of the host inflammatory response (Figure 2b). In the affected areas, atrophy of the epidermis with cytoplasmic vacuolisation of epithelial cells and absence of mucous cells was noticeable (Figure 3).

In recent years, organisms belonging to the class Mesomycetozoa have been considered a risk to aquatic and terrestrial animals (Mendoza et al., 2002; Glockling et al., 2013; Blazer et al., 2016). Several species of *Dermocystidium* sp. have been reported as pathogens of skin and gills in fish, resulting in dermocystidiosis that has a high mortality rate (Schäperclaus, 1992; Hassan et al., 2014). Diagnosis is usually performed by observing the typical occurrence of tubular cysts, spores with a refractile inclusion and subcutaneous lesions on the fish body (Ehab

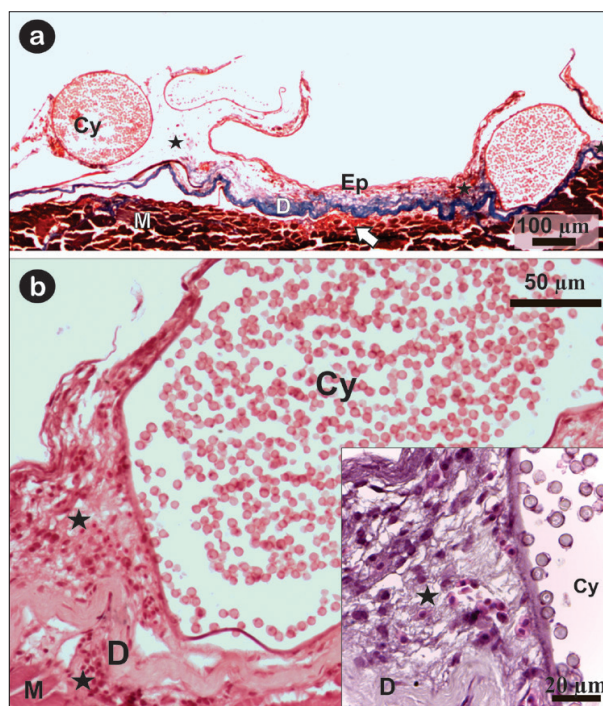


Figure 2. Cyst within the dermis extending to the epidermis as it increases in size. a) A microscopic view of tubular cyst, Masson's Trichrome stain; b) *Dermocystidium* sp. cyst with numerous intracystic spores. Inset: Infiltration of numerous inflammatory cells, mainly macrophages and lymphocytes. Cy: tubular cyst, Ep: epidermis, D: dermis, M: muscle, cellular infiltration (star), haemorrhagic area (arrow).

et al., 2002; Hassan et al., 2014; Langenmayer et al., 2015). To date, there are three reports on dermocystidiosis in neon tetra (Reichenbach-Klinke, 1982; Lewisch, 2010; Langenmayer et al., 2015). In this study, the lesions observed were similar to those described for other freshwater fish from farms, aquaria or wild fish. Since *Dermocystis pusula* Pérez was first described in 1907 parasitising newts, different species of *Dermocystidium* sp. have been reported as pathogens of other amphibians and fish in Europe, Asia and North America (Rowley et al., 2013). The first report of this parasite in South America came from Paraná River (Eiras and Silva Souza, 2000), while recently Fujimoto et al. (2018) reported occurrence of *Dermocystidium* sp. in the hybrid

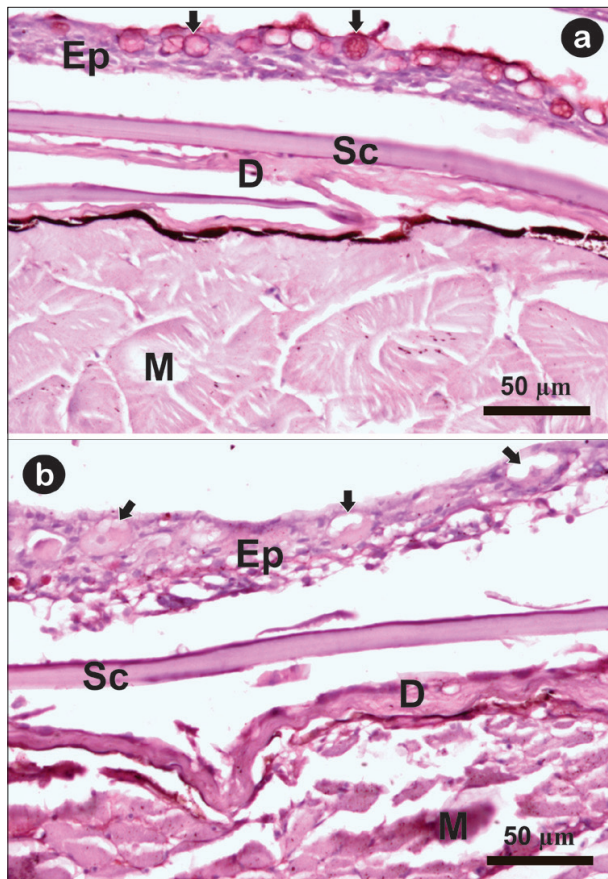


Figure 3. a) Normal epidermal tissue with mucous cells (arrows); b) Epidermal tissue near to the cysts. Note the absence of mucous cells, club cells with cytoplasmic vacuolisation (arrows) and loss of normal muscle architecture, PAS/H stain. Ep: epidermis, D: dermis, M: muscle, Sc: scale.

fish tambatinga (*Colossoma macropomum* Cuvier female x *Piaractus brachipomus* Cuvier male) farmed in freshwater earth ponds in Brazil.

Mendoza et al. (2002) suggested that fish became infected through exposure to uniflagellated zoospores that develop within cysts of infected or asymptomatic carrier fish. This is in accordance to our and previous observations (Reichenbach-Klinke, 1982; Lewisch, 2010; Langenmayer et al., 2015), as in the appearance of cysts was always observed a few weeks after the introduction of wild ornamental fish in tanks. Generally, in our country only a small percentage of species of ornamental interest are bred, while the majority

is obtained from natural environments. Thus, prevention through good management practices is the best control measure to minimise disease problems and fish mortality. An appropriate quarantine is of utmost importance for the new fish before their introduction in a community aquarium.

We wish to thank M. Fiorella Alvarado Pinedo and Gabriel Travería (*Centro de Diagnóstico e Investigaciones Veterinarias, CEDIVE*) for the technical assistance in bacteriological analysis. We thank Magdalena Ponce for editing the English text.

References

- APHA (1992). American Public Health Association. Standard Methods for the examination of water and wastewater. 18th edition, Washington DC. pp. 1316.
- Blazer VS, Hitt NP, Snyder CD, Snook EL and Adams CR (2016). *Dermocystidium sp.* Infection in Blue Ridge Sculpin Captured in Maryland. *Journal of Aquatic Animal Health* 28(3), 143-149.
- Chao NL (2001). The fishery, diversity and conservation of ornamental fishes in the Rio Negro basin, Brazil – A review of Project Piaba (1989–99). In “**Conservation and management of ornamental fish resources of the Rio Negro Basin, Amazonia, Brazil – Project Piaba Manaus: Editora da Universidade do Amazonas**” Chao NL, Petry P, Sonneschien PGL, Tlusty Meds. pp. 161-204.
- Doyle KA, Beers PT and Wilson DW (1996). Quarantine of aquatic animals in Australia. *Review Scientifique et Technique -OIE* 15, 659-673.
- Dungan CF and Bushek D (2015). Development and applications of Ray’s fluid thioglycollate media for detection and manipulation of *Perkinsus spp.* pathogens of marine molluscs.

Journal of Invertebrate Pathology **131**, 68-82.

Ehab EE, Ezz-Eldien NM and Mahmoud AM (2002). Nodular cap disease in the red oranda and red cap breeds of gold fish (*Carassius auratus*) associated with *Dermocystidium* species. *Bulletin of the European Association of Fish Pathologists* **22**(1), 7-14.

Eiras JC and Silva-Souza AT (2000). A *Dermocystidium* infection in *Trichomycterus* sp. (Osteichthyes, Trichomycteridae). *Parasite* **7**, 323-326.

Fujimoto RY, Couto MVS, Sousa NC, Dini DG, Dini JAP, Madi RR, Martins ML and Eiras JC (2018). *Dermocystidium* sp. infection in farmed hybrid fish *Colossoma macropomum* x *Piaractus brachypomus* in Brazil. *Journal of Fish Diseases* **41**, 565-568.

García-Gómez A, de la Gándara F and Raja T (2002). Utilización del aceite de clavo, *Syzygium aromaticum* L. (Merr. & Perry), como anestésico eficaz y económico para labores rutinarias de manipulación de peces marinos cultivados. *Boletín Instituto Español de Oceanografía* **18**, 21-23.

Glockling SL, Marshall WL, Gozlan RE, Marano AV, Lilje O and Gleason FH (2013). The ecological and economic importance of zoosporic Mesomycetozoean (Dermocystida) parasites of freshwater fish. In "**Freshwater Fungi and Fungal-like Organisms**" Jones EBG, Hyde KD, Pang KL, editors. Berlin, Germany. pp. 203-216.

Hassan MA, Osman HAM and Mahmoud MA (2014). Studies on Dermocystidiosis (yellow muscle disease) among some marine fishes of Arabian Gulf and Red Sea coast, Jeddah, Saudi Arabia. *Middle-East Journal of Scientific Research* **22**(4), 478-477.

Kim JH, Hayward CJ, Joh SJ and Heo GJ (2002). Parasitic infection in live Fresh water tropical fishes imported to Korea. *Diseases of Aquatic Organisms* **52**, 169-173.

Langenmayer MC, Lewisch E, Gotesman M, Hoedt W, Schneider M, El-Matbouli M and Hermanns W (2015). Cutaneous infection with *Dermocystidium salmonis* in cardinal

tetra, *Paracheirodon axelrodi* (Schultz, 1956). *Journal of Fish Diseases* **38**, 503-506.

Lewisch E (2010). *Dermocystidium* sp. bei Neon salmlern und Roten Neon. *Aqua Terra Austria* **6**, 34.

Mendoza L, Taylor JW and Ajello L (2002). The Class Mesomycetozoea: A heterogeneous group of microorganisms at the animal-fungal boundary. *Annual Review of Microbiology* **56**, 315-344.

Panné Huidobro S (2015). Estadísticas de importación y exportación de organismos acuáticos ornamentales durante el año 2014. Dirección de Acuicultura. Pp. 21. http://www.agroindustria.gov.ar/sitio/areas/acuicultura/publicaciones/_archivos//000000_Informaci%C3%B3n%20y%20noticias%20vinculadas%20al%20sector/160216_Estad%C3%ADsticas%20de%20Importaci%C3%B3n%20y%20Exportaci%C3%B3n%20de%20Organismos%20Acu%C3%A1ticos%20Ornamentales%20durante%20el%202014.pdf.

Plaul SE, Andrés Laube PF, Pacheco Marino SG, Santamaría Martín CJ, Moyano DA and Barbeito CG (2017). Morphological techniques used in ichthyopathological diagnosis. In "**Microscopy and imaging science approaches to applied research and education**" A. Méndez-Vilas Eds. Zaragoza, España. pp. 269-280.

Prang G (2007). An industry analysis of the freshwater ornamental fishery with particular reference to the supply of Brazilian freshwater ornamentals to the uk market. *UAKARI* **3**, 7-51.

Reichenbach-Klinke HH (1982). Eine *Dermocystidium*-Art im Neon fisch. *Aquarien-und Terrarien-Zeitschrift* **35**, 145.

Rowley JJJ, Gleason FH, Andreou D, Marshall WL, Lilje O and Gozlan R (2013). Impacts of mesomycetozoean parasites on amphibian and freshwater fish populations. *Fungal Biology Review* **27**, 100-111.

Schäperclaus W (1992). Mycoses. In "**Fish**

diseases Volume II" Schäperclaus W,
editor. Akademie-Verlag: Berlin, Germany.
Pp. 597-624.

Zehev BS, Almeida V, Benzaken A and Ribeiro
R (2015). Ornamental Fishery in Rio Negro
(Amazon region), Brazil: Combining Social,
Economic and Fishery Analyses. *Fisheries
and Aquaculture Journal* 6(4), 1000143.