

# Intentional Occlusion of the Left Subclavian Artery in Diseases of the Thoracic Aorta

MARCELO H. CERZO<sup>1</sup>

Bertoni and et al. (1) present an interesting experience in occlusion of the left subclavian artery (LSA) in order to improve the proximal fixation of tubular aortic endovascular devices to treat acute type B dissections (n = 4; 13.8%) or chronic (n = 14, 48.3%), intramural hematoma (n = 1; 3.4%), true aneurysm (n = 7; 24.1%), aortic ulcer (n = 1; 3.4%) and traumatic pseudoaneurysm (n = 2; 6.8%).

The percentage of occlusion of the subclavian artery in this series is similar to that observed in our series of patients.

The work has a good statistical analysis and is supported by an extensive and important bibliography. It has been recently suggested that the use of self-expanding devices with proximal end point with free flow stent in the treatment of aortic dissections carries some risk of complications, such as retrograde dissection to the ascending aorta. This complication is the result of trauma which can lead that bare stent. (2, 3) The incidence of stroke may reach 7% (4, 5) according to what was observed in the EUROSTAR registry.

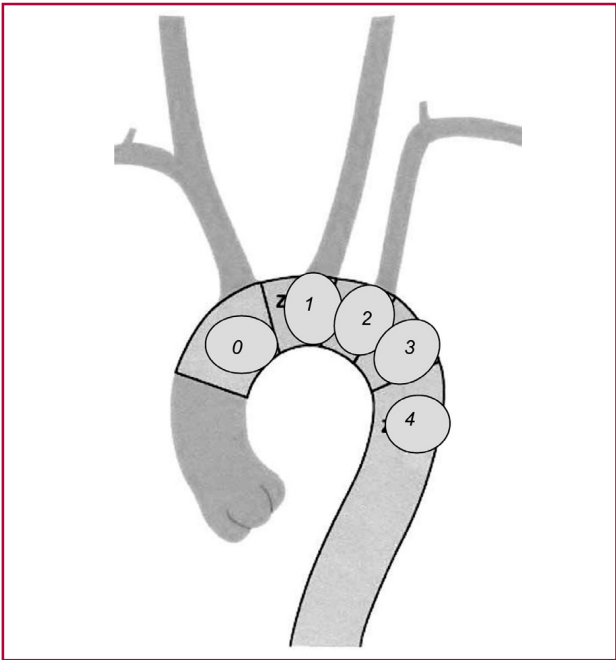
Referring to the topic of “overstretch” of the device, we consider that there should not be similar if the pathology to be treated were an atherosclerotic fusiform aneurysm or type B dissection. The objectives of treatment in these pathologies differ, since the aneurysm should be approximately oversized 15-20% in relation with the diameter of the healthy proximal aorta, while for the dissection, in our consideration, this oversize should not exceed 3mm that diameter (about 10% if it is considered a standard diameter of 30-36mm in the transverse aorta). This is because in the second mentioned pathology, the end point of treatment is the closure of the proximal tear (which, as it is known, in more than 80% it is within the first 2 left postsubclavian centimeters) and “restoration” of the true lumen, compressed, sometimes measuring no more than 10mm in diameter and sometimes virtually has collapsed under the pressure of the false lumen, thus higher the prosthetic diameter is, greater the risk of rupture of the flap, especially in acute or subacute. For the same reasons, the required length of the seating proximal and distal areas of the endoprotheses differ in both cases and it requires a greater length in the case of aneurysms (1.5 to 2cm), since a large part of the device will be literally “loose” in the aneurysm sac.

Regarding the opportunity for treatment of type B dissection, according to the INSTEAD trial publications, (6) which divided into two groups of patients with chronic B dissection, one to an endovascular treatment and the other to medical treatment, it is suggested that endovascular treatment indication would correspond in acute dissections, while that for chronic would be better the medical antihypertensive treatment tailored to each patient, although recent data is under review and should be added that several patients of the medical treatment of this study should go to the branch endovascular procedure, mainly due to growth in aortic diameter in the affected area. Regarding this comment, it should be noted that most of the patients treated by Bertoni and et al. were chronic type B dissections, but considering the start date of the experiment, there was no data on the indication in chronic patients.

As for the punctual fact of the left subclavian occlusion and as it was already mentioned, in 24% of our cases we carry out this gesture (similar to the percentage of Bertoni et al.) The reduction of systolic blood pressure in the left upper limb has been constant, although this did not lead to syndromes of poor perfusion of the limb, except for one case in which, unexpectedly, to ascend a catheter by the brachial artery there was a dissection of that vessel extended to the axillary artery, which produced an upper limb ischemia, evidenced by pain and pallor of the limb, which was resolved in 24 hours with the administration of vasodilator drugs.

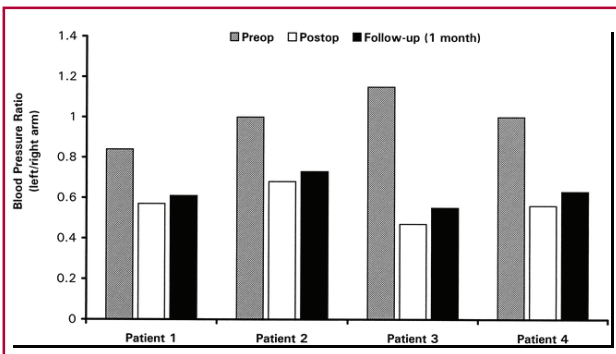
In 2002, Ishimaru divided the aortic arch into zones, in which in the zone 2 he involved the aorta with the ostium of the left subclavian artery, zone 1 corresponds to the aorta with the ostium of the left common carotid artery and the area 0 corresponds to the aorta with the ostium of the brachiocephalic arterial trunk (Figure 1). It is necessary, as it is mentioned in the work, to evaluate the state of the right vertebral artery and its continuation with the basilar artery, whether it is that a covered device will settle in zone 2. Similarly, as herein is mentioned, breast-coronary bypass patients should undergo coronary revascularization of the left subclavian artery prior to occlusion of the ostium. The carrying out of the bypass may be subclavian-carotid (direct terminolateral) or by interposition of a prosthetic segment, linking the subclavian always proximal to the vertebral origin.

<sup>1</sup> Associated Professor of Vascular Surgery, Facultad de Ciencias Médicas de la Universidad Nacional de La Plata  
Director of Instituto Argentino de la Aorta.



**Fig. 1.** Description of areas of the aortic arch according to Ishimaru (see explanation in the text).

Regarding the poor limb perfusion, several authors have studied it. (7, 8) As shown in Hausegger’s publication, there were measurements for the rate of pre-operation blood pressure, post-operation and at 30 days of following up of an intentional left subclavian occlusion; in all cases it was made evident a decline in postimplantation with a recovery also in all cases at 30 days (Figure 2). So too, a meta-analysis of the Nienaber group, 2004 shows the rate of poor limb perfusion (Table 1) which, incidentally, is rather low. With regard to the need to embolize the subclavian postimplantation ostium of stent-graft, we have carried out in two occasions and both times with vascular coils always proximal to the vertebral artery origin. This was necessary because, anatomically, the subclavian had a wide origin, constituting part with the beginning of the dilatation of the dissection, so that there was



**Fig. 1.** Description of areas of the aortic arch according to Ishimaru (see explanation in the text).

**Table. 1.** Rate of poor perfusion and steal of intentional subclavian postocclusion of the vessel ostium

	Number of patients	Poor intrahospital perfusion	Asymptomatic at follow-up	Delayed surgery for subclavian steal
Görich and et al.	23	3 (13%)	23 (100%)	0
Tiesenhausen and et al.	10	0	7 (70%)	1 (10%)
Palma and et al.	14	0	13 (93%)	1 (7%)
This study	22	0	15 (68%)	0
Total	69	3 (4.3%)	58 (84%)	2 (2.9%)

a retrograde perfusion into the false lumen. As the Amplatzer devices are also highly recommended for this purpose.

In short, this is a very interesting work, well documented, with good bibliography and iconographic material; likewise I congratulate the authors for the possibility of having such strict monitoring of this group of patients over the years, a situation that in our country is very difficult to accomplish.

**BIBLIOGRAPHY**

1. Bertoni HG, Azzari FA, Girela GA, Salvo GA, De La Vega A, Romero GA y col. Oclusión intencional de la arteria subclavia izquierda durante el tratamiento endovascular de la aorta torácica descendente. *Rev Argent Cardiol* 2011;79:XX-XX.
2. Fattori R, Lovato L, Buttazzi K, Di Bartolomeo R, Gavelli G. Extension of dissection in stent-graft treatment of type B aortic dissection: lessons learned from endovascular experience. *J Endovasc Ther* 2005;12:306-11.
3. Kasirajan K. Commentary on “Complicated acute type B dissection and endovascular repair: indications and pitfalls”. *Perspect Vasc Surg Endovasc Ther* 2007;19(2):160-1.
4. Dialetto G, Covino FE, Scognamiglio G, Manduca S, Della Corte A, Giannolo B, et al. Treatment of type B aortic dissection: endoluminal repair or conventional medical therapy? *Eur J Cardiothorac Surg* 2005;27(5):826-30.
5. Leurs LJ, Bell R, Degrieck Y, Thomas S, Hobo R, Lundbom J. On behalf of the EUROSTAR and the UK Thoracic Endograft Registry collaborators. Endovascular treatment of thoracic aortic diseases: combined experience from the EUROSTAR and United Kingdom thoracic endograft registries. *J Vasc Surg* 2004;40:670-80.
6. Nienaber CA, Zannetti S, Barbieri B, Kische S, Schareck W, Rehders TC, et al. Investigation of stent grafts in patients with type B aortic dissection: design of the INSTEAD trial a prospective, multicenter, European randomized trial. *Am Heart J* 2005;149:592-9.
7. Hausegger KA, Oberwalder P, Tiesenhausen K, Tauss J, Stanger O, Schedlbauer P, et al. Intentional left subclavian artery occlusion by thoracic aortic stent-grafts without surgical transposition. *J Endovasc Ther* 2001;8(5):472-6.
8. Rehders TC, Petzsch M, Ince H, Kische S, Körber T, Koschyk DH, et al. Intentional occlusion of the left subclavian artery during stent-graft implantation in the thoracic aorta: risk and relevance. *J Endovasc Ther* 2004;11(6):659-66.