

Hematological parameters and globulin profile of *Bothrops asper* and *Crotalus simus* snakes (Serpentes: Viperidae), after the main venom gland removal

Arturo Chang-Castillo¹, Randall Arguedas^{1,2}, Danilo Chacón¹, Greivin Corrales¹, Aarón Gómez¹

¹ Sección Serpentario, Instituto Clodomiro Picado, Facultad de Microbiología, Universidad de Costa Rica; San José, Costa Rica.

² Universidad Técnica Nacional, Sede Atenas; Alajuela, Costa Rica.

Recibido: 22 Octubre 2020

Revisado: 01 Diciembre 2020

Aceptado: 27 Diciembre 2020

Editor Asociado: C. Borteiro

doi: 10.31017/CdH.2021.(2020-081)

ABSTRACT

Snakebite accidents are a neglected tropical disease worldwide. In Costa Rica, the snakes *Bothrops asper* and *Crotalus simus* cause more than the 60% of the snakebite accidents already reported. To fight this neglected human disease, biomedical institutions need to manage live venomous snake collections in order to extract venoms and produce antivenoms. The welfare of the snakes in captivity must be guaranteed, especially in the case of old animals with defective venom production, which is a common situation at the Clodomiro Picado Institute. A surgical removal of the main venom glands was performed in five *B. asper* and *C. simus* with none or low venom production. The hematological parameters and plasma proteins of these individuals were analyzed pre-surgery and for 90 days post-surgery. Surgical procedures did not produce anemia during the post-surgical evaluation, but heterophilia, relative monocytosis and lymphopenia were detected one to three days afterwards. We conclude that the surgical removal of the main venom gland is a safe procedure and did not affect the snake's health. Additionally, the use of electrophoretic determination of the albumin:globulin ratio to assess the health condition of the snakes is discussed. Finally, the relative monocytosis and lymphopenia seems to be linked to continuous handling of the snakes during consecutive days. Monocytes play a key role in the stress response, therefore the relative monocytosis and lymphopenia of leukogram reports should be interpreted in this context.

Key Words: snake globulins, snake hematology, *Bothrops asper*, *Crotalus simus*, globulin profile, venomoid snakes.

Introduction

Costa Rica possess 23 venomous snakes of the 141 species reported to occur in this country, which represent a potential risk to humans, pets, and livestock (Leenders, 2019). Of these, *Bothrops asper* (Terciopelo snake) and *Crotalus simus* (Middle American rattlesnake), are the most important species regarding human snakebite accidents. The first is responsible for 50-60% of all cases reported (Sasa and Vázquez, 2003; Fernández and Gutiérrez, 2008). Thus, it is not surprising that the venoms of these snake species are widely used for antivenom production, like it takes place at the Instituto Clodomiro Picado from Costa Rica (Gutiérrez *et al.*, 2014).

In members of the families Elapidae, Viperidae and Atractaspidae, a relevant component of

the venom production system are the main venom glands that synthesize, store, and secrete the proteins conforming the venom. The glands differ in shape and size of the lumen, as well as in the distribution of their mucous and serous cells (Jackson, 2007). These glands are covered by connective tissue, which is attached to the compressor muscles; the muscles are responsible for contracting the glands in order to eject the venom when biting (Mackessy, 1991). In viperids, the main gland drains the venom into a primary duct that is typically absent in elapids (Mackessy, 1991; Sakai *et al.*, 2012).

It is known that after years of extracting venom for biomedical purposes, the viperid main venom glands become dysfunctional and stop producing

venom, mainly due to a mild to severe trauma caused by the mechanical pressure applied to the glands during extraction (Giannotti *et al.*, 2013; Rodríguez-Abarca *et al.*, 2019). This repetitive traumatic injury induces venom leaking that affects the surrounding tissue, and the glands may undergo fibrotic dysplasia (Rodríguez-Abarca *et al.*, 2019). For this reason, removal of the main venom glands is desirable as they may affect the welfare of the snakes; these snakes without the main venom gland are called venomoids (Bielli and Silvetti, 2014).

Unfortunately, there is a scarce number of scientific articles dealing with hematology, blood biochemistry and some associated clinical aspects in reptiles, especially in venomous snakes (Giménez *et al.*, 2010; Lentini *et al.*, 2011; Melillo, 2013; Gómez *et al.*, 2016). Performing hematology tests and leukogram readings may help in disease diagnosis and reveal inflammatory responses in snakes, particularly to evaluate post-surgical performance as they are fast and simple methods. Furthermore, there is evidence that heterophil counts in snakes increase after surgical procedures, as do monocytes related to chronic infections, while lymphocytes and basophils increase in response to foreign bodies such as telemetric transmitters (Lentini *et al.*, 2011).

Plasma proteins serve a myriad of functions, i.e., maintaining blood osmotic pressure, pH regulation, hormone and drug transport, blood clotting (Melillo, 2013), immune and inflammatory reactions and tissue repair (Thrall *et al.*, 2012). Nevertheless, there are still no studies related to *B. asper* and *C. simus* plasma proteins.

In birds and reptiles, the plasma proteins migrate similarly in gel electrophoresis, according to their electric charges. The order of the plasma proteins fractions usually seen in a gel is: albumins, α 1-globulins, α 2-globulins, β -globulins y γ -globulins, with albumin exhibiting the highest negative charge and the lowest molecular weight, while globulins the low negative charge and higher molecular weight. Furthermore, there is a prealbumin fraction also, with higher negative charge than albumins (Melillo, 2013), with and a hypothetical function of transport, named bisalbumins (Giménez *et al.*, 2010).

In snakes, albumins are the predominating plasma proteins, while globulins are at a very low concentration in healthy individuals (Thrall *et al.*, 2012; Campbell, 2015). Therefore, it is possible to observe differences in the electrophoretic patterns of plasma proteins in sick and healthy individuals

(Zaias and Cray, 2002). The albumin:globulin (A:G) ratio is another tool used to evaluate variations in plasma proteins that can be used to determine dysproteinemia, even when the total protein level is normal (Melillo, 2013). This ratio can also aid to identify hypoalbuminemia, which could be a sign of anorexia, enteropathies, nephropathies, or liver disease (Silva *et al.*, 2011), and also hyperalbuminemia as a possible sign of dehydration (Divers, 2000). Nonetheless, it must be considered that the technique has a high variability and value in diagnostics because of the variations related to species, sex, temperature, humidity, photoperiod, nutrition, and season (Melillo, 2013; Silva *et al.*, 2011).

Hence, the aim of this study was to determine some electrophoretic and hematological parameters of viperid snakes after a surgical procedure. Since the World Health Organization (WHO) declared the snakebite in the Neglected Tropical Diseases Category A list (Chippaux, 2017), it is extremely important to generate clinical knowledge on how to approach the welfare of snakes kept in captivity for antivenom research and production.

Materials and methods

This study was approved by the “Comité Institucional para el Cuido y Uso de Animales de Laboratorio (CICUA)” of Universidad de Costa Rica (CICUA-033-17 and CICUA-82) and meet the International Guiding Principles for Biomedical Research Involving Animals (CIOMS, 1986). We followed the Legislation for the protection of animals used for scientific purposes (Directive 2010/63/EU, Commission Implementing Decision 2012/707/EU, Recommendation 2007/526/EC), and Animal Research: Reporting of In Vivo Experiments (ARRIVE) guidelines for designing and conducting all experiments involving animals; and “Ley 7317: Ley de Conservación de la Vida Silvestre” legislation for Costa Rica.

Snakes.

Bothrops asper and *Crotalus simus* individuals we studied belong to the snake collection from the Instituto Clodomiro Picado’s Serpentarium. They were kept in 62x32x23 cm acrylic cages with aluminum lids, at an environmental humidity of 80-90%. The environmental temperature was between 22-26°C and 28-30°C for *B. asper* and *C. simus* respectively. The snakes were fed every 10 days with four adult (+22g body weight) albino mice (*Mus musculus*, stra-

in CD-1). Two groups of five adult snakes were conformed for both species, corresponding one to the control group and another one in which the venom gland was surgically removed (venomoid group). The venomoid group included adult individuals of both species which were not able to produce more venom, or whose venom yield production had been very low for several consecutive venom extraction procedures.

Venom glands removal surgery.

For the excision of venom glands in *B. asper* and *C. simus* individuals were anesthetized with 4 mg/kg of Propofol and 10mg/kg of Ketamine; two analgesics were used: Tramadol 5mg/kg of and Meloxicam 0.2 mg/kg. Drugs were administered intramuscularly except for Propofol, which was injected intravenously.

The surgery consisted in making an incision between the oral and labial mucosa lining, starting at the eye's medial canthus, and ending at the mandibular commissure. After that, the superficial adductor muscle was separated from the glandular joint in the caudal region of the gland; then, the square ligament that gives support to the posterior region of the gland was cut. Once separated, the gland was extracted and its conduct communicating with the accessory gland was ligated with absorbable suture (Vycril 4-0[®]). Finally, the initial incision was closed with non-absorbable suture (Vycril 4-0[®]).

After the surgery, the following medications were injected intramuscularly daily: Ceftriaxone 50 mg/kg for five days, Enrofloxacin 10 mg/kg for 10 days, Ketoprofen 2mg/kg for five days and Tramadol 5mg/kg for three days.

Blood extraction and handling.

Blood was extracted from the caudal vein with a 22-gauge in a 3 mL syringe, before surgery, immediately afterwards, and also 3, 30, 60 and 90 days later. The amount of blood extracted was 1 mL, but not surpassing the 0.8% of the individual's body weight, as recommended by Allender *et al.* (2006). Blood samples were kept in tubes with heparin, and immediately used for the estimation of hemoglobin and hematocrit, as described elsewhere (Thrall *et al.*, 2012; Campbell, 2015). Then, plasma was separated from cells by centrifugation and frozen at -20°C until used. Five healthy venom producing snakes of both species were used as negative controls and submitted to the same conditions of handling and blood withdrawal.

Hematological analysis

The hematological tests were performed manually by two independent technicians following the methods described by Salakij (2002), in which blood smears are air dried before staining with Wright stain. Leukocytes were classified as heterophils, eosinophils, basophils, monocytes, and lymphocytes according to Thrall *et al.* (2012). All tests were made in duplicates, and values are expressed as mean \pm standard deviation (SD).

Analyses of plasma proteins.

To determine plasma protein concentration, 2 μ L of each sample were loaded and measured at 280 nm in a NanoDrop 2000 Spectrophotometer. Protein electrophoresis (SDS-PAGEs) were carried out at 7.5% under non-reducing conditions and run at 180V. The wells were loaded with 6 μ L of sample at a plasma protein concentration of 1.5 μ g/ μ L (9 μ g of protein per well), and 3 μ L of molecular weight marker (Precision Plus Protein Dual Color Standard, Bio-Rad) were used. Gels were photographed, and edited in a Bio-Rad ChemiDoc XRS, used also to generate a report with the relative density percentages for each band on every lane. These relative percentages were used to calculate the albumin:globulin (A:G) ratio, with the globulin relative values obtained by the sum of the bands corresponding to α - (~75 kDa), β - (~150 kDa) and γ -globulins (~250 kDa), while the albumins are just one band at ~50 kDa (Thrall *et al.*, 2012; Melillo, 2013; Campbell, 2015).

Statistical analysis.

A repeated-measure ANOVA was performed to assess the variation of the hematological parameters through time, as well as the comparisons between venomoids and control snakes in both species; we used it also to test for differences in the albumin:globulin ratio of both species during the study. The sphericity assumption was tested by Mauchly's test, and when the assumption was not achieved, the Greenhouse-Geisser correction factor was used. All values with $p < 0.05$ were considered as statistically significant.

Results

Hematological analysis.

Within group differences in the hematocrit were observed for both *B. asper* ($F = 4.923$, $df = 5$, $p = 0.004$) and *C. simus* ($F = 3.342$, $df = 5$, $p = 0.013$), during the experiment. When the hematocrit value of venomoid

B. asper was compared against its control group, no differences were observed ($F= 2.509$, $df= 5$, $p= 0.064$); the same occurred with *C. simus* ($F= 1.853$, $df= 5$, $p= 0.125$) (Table 1). Venomoid snakes of both species showed a decrease in the hematocrit content until day 60, then a slightly recover until the end of the study was recorded (Table 1).

Regarding the hemoglobin concentration, the venomoid group of *B. asper* did not show differences when compared through time ($F= 1.017$, $df= 5$, $p= 0.434$), nor when compared against control snakes ($F= 0.994$, $df= 5$, $p= 0.447$). Conversely, the hemoglobin content in *C. simus* venomoids showed differences through time ($F= 17.151$, $df= 5$, $p< 0.001$), as well as when compared against its controls ($F= 12.239$, $df= 5$, $p< 0.001$) (Table 1). A three-fold increase after one day post-surgery was recorded, but a decrease occurred by day 30 after surgery. Interestingly, this hemoglobin concentration of venomoid *C. simus* 30 days after surgery did not coincide with the hematocrit data (Table 1).

Regarding leukocytes, the relative percentage of monocytes for *B. asper* varied during the experiment ($F= 3.877$, $df= 5$, $p= 0.019$), but not when compared with control snakes ($F= 1.697$, $df= 5$, $p= 0.196$). The basophils did not vary during time ($F= 1.683$, $df= 5$, $p= 0.199$), nor between control and venomoid snakes ($F= 1.814$, $df= 5$, $p= 0.171$). The eosinophils did not show differences neither during the experiment ($F= 0.688$, $df= 5$, $p= 0.674$), nor between control and operated snakes ($F= 0.941$, $df= 5$, $p= 0.483$). Similar variation presented the heterophils during time ($F= 2.399$, $df= 5$, $p= 0.087$), and between control and venomoid snakes ($F= 2.168$,

$df= 5$, $p= 0.113$). The lymphocytes varied during the experiment ($F= 4.821$, $df= 5$, $p= 0.008$), but did not show significant differences when the control and venomoid snakes were compared ($F= 2.358$, $df= 5$, $p= 0.091$) (Table 2).

In venomoids *B. asper*, a relative monocytosis is evident at day one that is concurrent with an inverse relative lymphopenia. However, high levels of monocytes and lymphocytes were maintained during the study; as well as a moderate relative increase in heterophils was found in venomoids *B. asper* (Table 2). Whereas in control *B. asper* a relative monocytosis and an inverse relative lymphopenia was recorded at day three, as well as an increase in heterophils (Table 2).

Regarding the relative percentage of monocytes in *C. simus*, they varied during the experiment ($F= 12.174$, $df= 5$, $p< 0.0001$), but did not differ when the venomoid and control rattlesnakes were compared ($F= 2.135$, $df= 5$, $p= 0.081$). The basophils of venomoids did not vary during the experiment ($F= 2.009$, $df= 5$, $p= 0.098$), nor when compared with the control snakes ($F= 0.225$, $df= 5$, $p= 0.950$). The eosinophils did also not vary with time ($F= 1.740$, $df= 5$, $p= 0.148$), nor when they were compared with those of control snakes ($F= 0.803$, $df= 5$, $p= 0.555$). The heterophils showed a differential behavior during the study ($F= 3.485$, $df= 5$, $p= 0.010$), and also when compared with the control group ($F= 2.754$, $df= 5$, $p= 0.031$). Similarly, the lymphocytes varied through time ($F= 9.629$, $df= 5$, $p< 0.0001$) and when compared with controls ($F= 2.597$, $df= 5$, $p= 0.040$) (Table 2).

In summary, a relative monocytosis and an

Table 1. Hematocrit and hemoglobin values of *Bothrops asper* and *Crotalus simus* snakes. A comparison between control group (CG) and surgically venom gland removed or venomoid group (VG) is provided. All values are shown as mean \pm SD.

Hematological Parameter	Days	<i>B. asper</i> VG	<i>B. asper</i> CG	<i>C. simus</i> VG	<i>C. simus</i> CG
Hematocrit (%)	0	22.8 \pm 3.0	21.8 \pm 5.7	25.4 \pm 1.8	22.8 \pm 1.2
	1	20.5 \pm 7.8	22.1 \pm 5.1	21.5 \pm 2.4	15.6 \pm 5.3
	3	17.0 \pm 2.8	15.9 \pm 9.1	15.6 \pm 4.0	23.0 \pm 3.8
	30	15.3 \pm 3.2	18.8 \pm 3.6	19.2 \pm 6.1	22.4 \pm 2.5
	60	15.0 \pm 2.6	17.7 \pm 3.2	20.1 \pm 5.5	27.1 \pm 5.9
	90	18.2 \pm 3.7	11.5 \pm 3.3	22.3 \pm 5.8	22.3 \pm 3.6
Hemoglobin (g/dl)	0	7.8 \pm 1.8	5.7 \pm 1.9	10.7 \pm 0.5	10.2 \pm 2.7
	1	9.7 \pm 6.0	6.1 \pm 4.0	28.9 \pm 11.9	8.1 \pm 1.3
	3	6.1 \pm 1.2	6.9 \pm 2.9	4.3 \pm 1.4	7.4 \pm 0.6
	30	6.2 \pm 0.3	6.4 \pm 2.1	2.1 \pm 1.8	3.9 \pm 1.8
	60	6.8 \pm 3.9	6.1 \pm 2.4	8.7 \pm 3.7	9.3 \pm 3.0
	90	7.0 \pm 0.7	7.0 \pm 3.2	8.5 \pm 4.2	7.3 \pm 1.5

Table 2. Leukogram values of *Bothrops asper* and *Crotalus simus* snakes. A comparison between control group (CG) and surgically venom gland removed or venomoid group (VG) is provided. All values are shown as mean \pm SD.

Leukocyte cell type (%)	Days	<i>B. asper</i> VG	<i>B. asper</i> CG	<i>C. simus</i> VG	<i>C. simus</i> CG
Monocytes	0	19 \pm 9	13 \pm 2	27 \pm 5	19 \pm 3
	1	40 \pm 2	26 \pm 14	47 \pm 19	41 \pm 8
	3	48 \pm 5	22 \pm 11	45 \pm 13	31 \pm 10
	30	9 \pm 4	18 \pm 16	16 \pm 4	25 \pm 6
	60	15 \pm 8	10 \pm 4	19 \pm 10	24 \pm 15
	90	17 \pm 10	14 \pm 9	20 \pm 7	22 \pm 11
Basophils	0	0 \pm 1	0 \pm 0	1 \pm 1	1 \pm 2
	1	3 \pm 4	1 \pm 1	2 \pm 2	1 \pm 2
	3	5 \pm 6	1 \pm 1	1 \pm 1	1 \pm 1
	30	1 \pm 2	1 \pm 1	1 \pm 1	1 \pm 1
	60	3 \pm 4	1 \pm 1	1 \pm 1	1 \pm 1
	90	2 \pm 2	0 \pm 1	0 \pm 1	0 \pm 1
Eosinophils	0	0 \pm 0	0 \pm 0	0 \pm 1	0 \pm 1
	1	0 \pm 0	2 \pm 4	3 \pm 6	1 \pm 2
	3	0 \pm 0	1 \pm 1	2 \pm 3	0 \pm 0
	30	1 \pm 1	0 \pm 0	2 \pm 2	0 \pm 1
	60	0 \pm 0	0 \pm 0	1 \pm 1	0 \pm 0
	90	0 \pm 1	0 \pm 0	0 \pm 0	0 \pm 0
Heterophiles	0	5 \pm 5	7 \pm 5	3 \pm 4	6 \pm 9
	1	13 \pm 8	15 \pm 10	7 \pm 8	7 \pm 5
	3	29 \pm 14	13 \pm 13	26 \pm 16	8 \pm 5
	30	19 \pm 15	11 \pm 15	16 \pm 11	10 \pm 5
	60	15 \pm 1	5 \pm 3	22 \pm 13	10 \pm 6
	90	5 \pm 4	9 \pm 11	12 \pm 10	8 \pm 5
Lymphocytes	0	75 \pm 12	80 \pm 6	68 \pm 5	71 \pm 7
	1	44 \pm 24	56 \pm 19	40 \pm 25	49 \pm 14
	3	19 \pm 3	65 \pm 25	27 \pm 8	59 \pm 9
	30	69 \pm 17	70 \pm 20	65 \pm 10	64 \pm 8
	60	67 \pm 10	84 \pm 6	57 \pm 7	64 \pm 15
	90	76 \pm 11	77 \pm 15	68 \pm 12	69 \pm 16

inverse relative lymphopenia was observed at day one in venomoid *C. simus*. Moreover, a moderate increase in the relative percentage of heterophils during the study was registered; as well as high levels of monocytes and lymphocytes (Table 2). In control *C. simus*, the same phenomenon of relative monocytosis and an inverse relative lymphopenia was observed at day three, as well as an increase in heterophils (Table 2).

SDS-PAGE and albumin:globulin ratio.

The A:G ratio of *Bothrops asper* did not differ during the study ($F=0.269$, $df=5$, $p=0.923$) nor when com-

pared with control snakes through time ($F=0.328$, $df=5$, $p=0.889$) (Table 3). The A:G ratio of venomoid *C. simus* significantly varied during the experiment ($F=3.217$, $df=5$, $p=0.017$), but when compared to controls no differences were observed ($F=2.268$, $df=5$, $p=0.069$) (Table 3).

The electrophoretic profile of a venomoid and a control *B. asper* and *C. simus* snakes is shown in Figs. 1 and 2. Although variable, the A:G ratios for either venomoid or control *B. asper* snakes maintained a 1.5 proportion, whereas, the ratio on the venomoid *C. simus* varied at 30 days after surgery but not in the controls during the whole experiment.

Table 3. The albumin:globulin ratio values of *Bothrops asper* and *Crotalus simus* snakes. A comparison between control group (CG) and surgically venom gland removed or venomoid group (VG) is provided. All values are shown as mean \pm SD.

Group	0 days	1 day	3 days	30 days	60 days	90 days
<i>B. asper</i> VG	2.23 \pm 1.30	1.49 \pm 0.19	1.27 \pm 0.01	2.02 \pm 1.97	1.94 \pm 0.73	2.09 \pm 1.01
<i>B. asper</i> CG	1.07 \pm 0.50	0.99 \pm 0.50	1.03 \pm 0.50	1.08 \pm 0.47	1.34 \pm 0.87	1.34 \pm 0.90
<i>C. simus</i> VG	1.68 \pm 0.47	1.67 \pm 1.01	1.65 \pm 0.53	2.59 \pm 1.45	1.74 \pm 0.41	1.73 \pm 0.41
<i>C. simus</i> CG	1.60 \pm 0.55	1.65 \pm 0.36	1.50 \pm 0.28	1.65 \pm 0.51	1.37 \pm 0.38	1.60 \pm 0.80

Discussion

The generation of valuable clinical information in snakes, especially in venomous species, is a difficult task. Besides, baseline information available to aid in diagnosis is scarce. Nevertheless, recent efforts in this regard have been conducted in snake collections established for biomedical purposes (Thrall *et al.*, 2012; Melillo, 2013; Campbell, 2015; Gómez *et al.*, 2016; Rodríguez-Abarca *et al.*, 2019).

It was demonstrated that manual venom extraction in crotaline viperids (i.e., genus *Bothrops* and *Crotalus*), affects the glandular tissues and the venom yield (Giannotti *et al.*, 2013; Rodríguez-Abarca *et al.*, 2019). This damage leads to a fibrotic tissue generation, switching from normal glandular tissue to a high content of collagen scar tissue. Moreover, this process could be harmful for the snake's homeostasis, with the occurrence of edema, hemorrhage, and necrosis (Giannotti *et al.*, 2013;

Rodríguez-Abarca *et al.*, 2019). Additionally, it may cause indirect effects such as pro-inflammatory activity due to venom leakage (Clissa *et al.*, 2001; Teixeira *et al.*, 2003; Moreira *et al.*, 2012).

In general terms, hematocrit of *B. asper* and *C. simus* snakes were within the 95% reference interval (RI) reported by Gómez *et al.* (2016). However, the hematocrit values of *B. asper* venomoids tend to decrease after day one as well as in its control counterparts. Whereas *C. simus* venomoids showed a decrease in hematocrit value at day three and day 30, control *C. simus* snakes showed a decrease at day one (Table 1). This phenomenon could be related to the environmental (physical) conditions in which both snake species were kept. *Crotalus simus* snakes were maintained at higher temperatures and low relative humidity as compared to *B. asper*, which would have favored an increase in the metabolic rate and consequently an enhanced erythropoietic response (Thrall *et al.*, 2012; Campbell, 2015). The

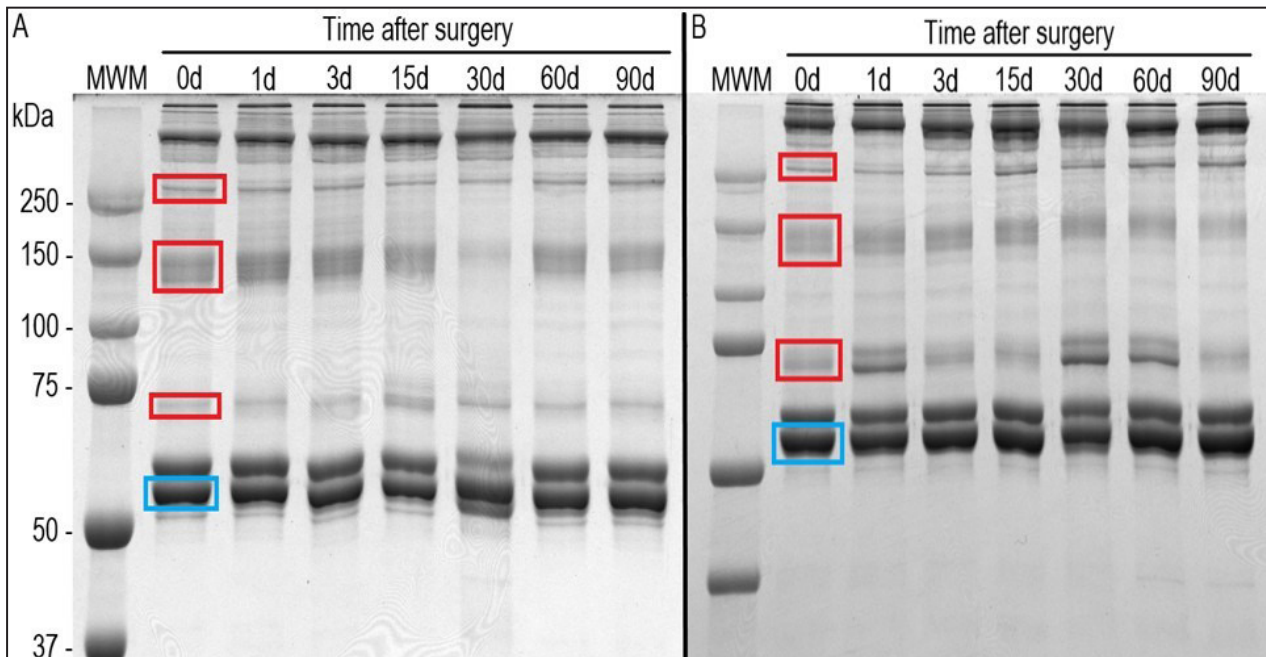


Figure 1. SDS-PAGE profile of *Bothrops asper* blood serum samples taken at different time intervals after main venom glands removal (A), and comparison with a control individual (B). Light-blue square marks the protein bands corresponding to albumins; red squares mark the protein bands corresponding to globulins.

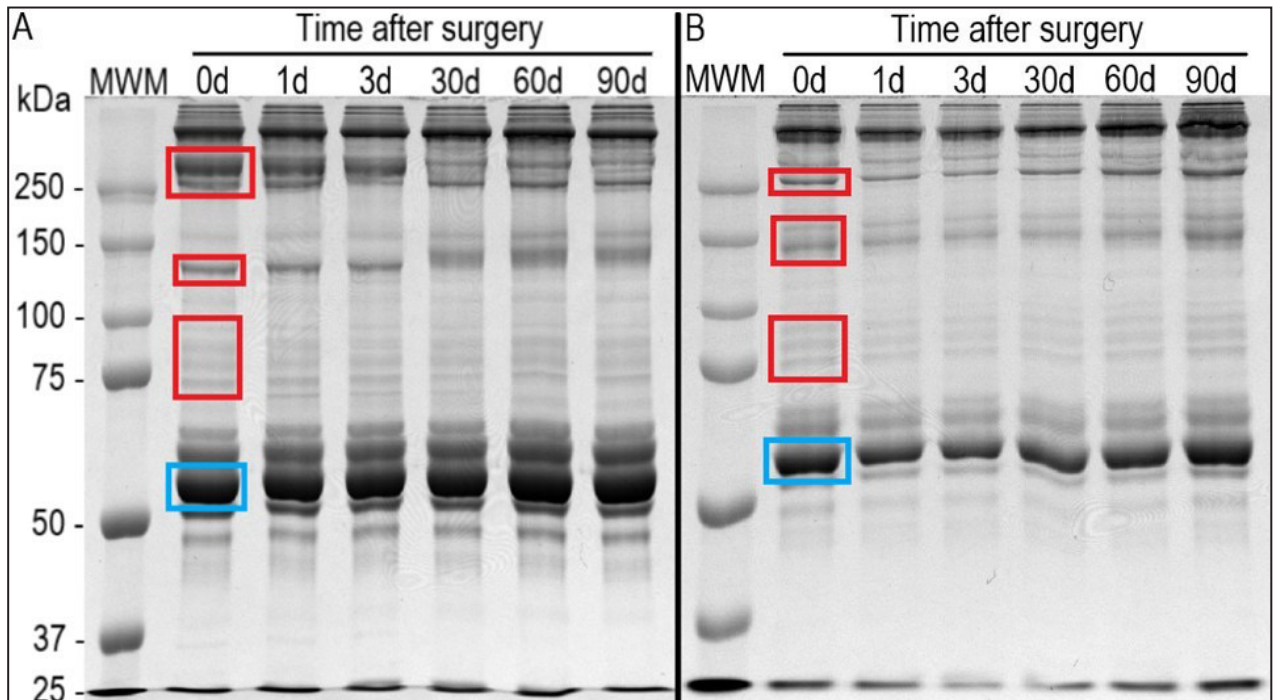


Figure 2. SDS-PAGE profile for *Crotalus simus* blood serum samples taken at different time intervals after main venom glands removal (A), and comparison with a control individual (B). Light-blue square marks the protein band corresponding to albumins; red squares mark the protein bands corresponding to globulins.

hematocrit levels of snakes could change depending on the environmental conditions (Brischoux *et al.*, 2011; Thrall *et al.*, 2012), and one major abiotic factor affecting snake metabolism is temperature. Hemoglobin displays lower oxygen affinity at higher temperatures (Weber and Campbell, 2011), and this may have induced a faster production of red blood cells in *C. simus*. Additionally, it is not possible to consider a post-surgical anemia since the variations in the hematocrit values were not different through the time in both species; *B. asper* ($p= 0.064$) and *C. simus* ($p= 0.125$).

The hemoglobin content for *B. asper* and *C. simus* were within the 95% reference interval (RI) described by Gómez *et al.* (2016). Nonetheless, venomoid *C. simus* showed a slightly high hemoglobin content pre- surgery, by day zero. An outlier value was registered at day one in *C. simus* venomoids, which could be due to a methodological artifact. However, a further research on this particular feature is needed.

The scarce variation of hemoglobin content in both species suggests that the surgical procedure did not produced anemia. However, there is a discrepancy between hematocrit and hemoglobin values in *C. simus* at days three and 30. Unlike other vertebrates,

reptile rubricytes mature in peripheral blood (Stacey *et al.*, 2011; Thrall *et al.*, 2012; Campbell, 2015), instead in the bone marrow. A possible explanation could be the detection of recently produced rubricytes by the hematocrit, but these immature cells bear hemoglobin content (Thrall *et al.*, 2012; Campbell, 2015).

Regarding the leukocytes, the basophils and the eosinophils values were within the 95% RI reported by Gómez *et al.* (2016) for both snake species. However, a relative heterophilia, and an inverse relative monocytosis and lymphopenia was evident for at least three days, regardless the species. Because there were no drastic variations of basophils and eosinophils, we can assume a relatively good health condition in the snakes studied. Since basophilia may be associated to blood microparasites and viral infections, while eosinophilia is a common response to macroparasites and non-specific immune stimulations (Thrall *et al.*, 2012; Campbell, 2015).

On the other hand, heterophilia is regarded as a normal response to inflammation caused by infection (i.e., bacteria, parasites), or other tissue injuries including necrosis (Thrall *et al.*, 2012; Campbell, 2015). The heterophilia observed in *B. asper* although is evident, was not different between

venomoids and controls ($p= 0.113$). In contrast, the phenomenon is evident when venomoid and control *C. simus* snakes are compared ($p= 0.031$), supporting the general idea of heterophilia caused by tissue damage and inflammatory processes after surgical procedures.

Lymphopenia has been associated with malnutrition and with excess of endogenous or exogenous corticosteroids (Thrall *et al.*, 2012; Campbell, 2015). The decrease observed in both, *B. asper* and *C. simus* during the whole study especially at day three as no differences were observed between *B. asper* venomoids and controls ($p= 0.091$), the lymphopenia was likely caused by the continuous handling of the snakes in both groups (Arguedas *et al.*, 2018). Additionally, *C. simus* snakes seem to be more sensitive to continuous handling because venomoids showed a more marked decrease than controls (Table 2).

The monocytes increase with antigenic stimulation and their increment is suggestive of chronic infections (Thrall *et al.*, 2012; Campbell, 2015). Monocytosis is also involved in granulomas and giant cell formation and is specifically associated with granulomatous responses to bacterial infections (Thrall *et al.*, 2012; Campbell, 2015). Although monocytosis was evident in both species after surgery, *B. asper* ($p= 0.019$) and *C. simus* ($p < 0.0001$), there were no significant differences within species ($p= 0.196$; $p= 0.081$; respectively). We argue again for an effect of continuous handling of snakes (Arguedas *et al.*, 2018), rather than being caused by the surgery.

The albumin:globulin (A:G) ratio of the electrophoretic report, could give a general idea on the health state of the individual. The A:G ratio for both snake species could be considered as stable, without a hyper-stimulation of globulin production like in an immune response, that was not the case due to a surgical intervention. Regarding the assessment of health condition, the A:G ratio is a good indicator since α -globulin hyperglobulinemia has been associated with necrosis, whereas a decrease in α -globulins indicates malnutrition, enteropathy and/or chronic renal disease (Campbell, 1996; Thrall *et al.*, 2012; Divers, 2000; Campbell, 2015).

Additionally, hyper- and hypoalbuminemia are indicators of poor health condition in snakes. Low levels of serum albumins may be indicative of liver failure, chronic malnutrition, glomerular diseases, and end-stage renal disease; also, it is present in other gastrointestinal, liver, and cardiovascular diseases (Mader, 2006). Hyperalbuminemia is typically as-

sociated with dehydration and diets with excess of protein. There is direct association of hyperalbuminemia with renal disease, although it may be present while dehydration is present in patients with renal failure (Thrall *et al.*, 2012; Campbell, 2015).

Measurements of A:G ratio may be clinically relevant, especially as an aid to detect post-surgical alterations of snake's homeostasis. This kind of alteration was observed in *Iguana iguana* (Zaias and Cray, 2002), in which healthy and sick animals had marked differences in their serum protein electrophoretic pattern.

The A:G ratio slightly decreased in venomoid *B. asper* snakes at day one and day three, whereas in venomoid *C. simus* snakes, slightly increased at day 30. It must be noted that the environmental conditions in which *C. simus* snakes were kept (specially temperature), would have induced temporarily slight dehydration in some specimens (Divers, 2000). However, other unidentified factors associated to surgery may be involved in the case of *B. asper*. Slight dehydration is not necessarily clinically relevant information in our conditions since no other clinical alterations were detected.

Conclusion

The surgical method used to remove the main venom gland and the post-surgical treatment did not affect the overall health condition in two snake species. The procedures did not alter the hematocrit, hemoglobin value, and the percentage of eosinophils and basophils, providing the first insights into hematological and blood biochemistry parameters in two neotropical viper snakes after surgical procedures.

The heterophilia we observed could be attributed to a natural event caused by the surgically removal of tissue that cause damage and inflammation in the mouth cavity and surrounding musculature.

The relative monocytosis and relative lymphopenia seems to be directly linked to a continuously handling of the snakes and evidence stress. Monocytes may play a key role in the stress response of *B. asper* and *C. simus*, and presumably pit vipers and snakes in general.

Finally, the determination of A:G values in both species indicated no major metabolic affection of individuals post- surgery. The good recovery process under stable rearing conditions in our experiment (i.e., temperature, relative humidity, diet, and water supply) indicates adequate post-surgical han-

ding of the snakes (i.e., antibiotics and analgesics).

Acknowledgments

This study was partially supported by Vicerrectoría de Investigación, Universidad de Costa Rica, grant # 741-B7-107. Additionally, the authors want to thank the comments and suggestions made by the reviewers, which definitively increased the quality of this work.

Literature cited

- Allender, M.C.; Mitchell, M.A.; Phillips, C.A.; Gruszynski, K.; Beasley, V.R. 2006. Hematology, plasma biochemistry, and antibodies to select viruses in wild-caught Eastern massasauga rattlesnakes (*Sistrurus catenatus catenatus*) from Illinois. *Journal of Wildlife Diseases* 42:107-114.
- Arguedas, R.; Gómez, A.; Barquero, M.D.; Chacón, D.; Corrales, G.; Hernández, S. & León, G. 2018. Effect of exposition to chlorpyrifos upon plasmatic cholinesterases, hematology and blood biochemistry values in *Bothrops asper* (Serpentes: Viperidae). *Chemosphere* 205: 209-214.
- Bielli, M. & Silveti, S. 2014. Venomoid surgery in venomous snakes: surgical technique and follow up. *Journal of Herpetological Medicine and Surgery* 24: 43-47.
- Brischoux, F.; Gartner, G.E.; Garland Jr, T. & Bonnet, X. 2011. Is aquatic life correlated with an increased hematocrit in snakes? *PLOS One* 6: e17077.
- Campbell, T.W. 1996. Clinical pathology. In Mader D.R. (ed), *Reptile Medicine and Surgery*. 1st ed. Philadelphia: W.B. Saunders Co. p.248-257
- Campbell T.W. 2015. In Campbell T.W (ed), *Exotic Animal Hematology and Cytology*, 4th ed, Wiley-Blackwell, United States.
- Chippaux, J.P. 2017. Snakebite envenomation turns again into a neglected tropical disease! *Journal of Venomous Animals and Toxins including Tropical Diseases* 23: 38.
- Bankowski, Z. & Howard-Jones, N. 1986. The International Guiding Principles for Biomedical Research Involving Animals. In: CIOMS (Council of International Organizations of Medical Science). Geneva.
- Clissa, P.B.; Laing, G.D.; Theakston, R.D.G.; Mota, I.; Taylor, M.J. & Moura-da-Silva, A.M. 2001. The effect of jararhagin, a metalloproteinase from *B. jararaca* venom, on pro-inflammatory cytokines released by murine peritoneal adherent cells. *Toxicon* 39: 1567-1573.
- Divers, S.J. 2000. Reptilian liver and gastrointestinal testing. In Fudge AM (ed), *Laboratory Medicine: Avian and Exotic Pets*. 1st ed, Philadelphia: W.B. Saunders Co. p. 205-209.
- Fernández, P. & Gutiérrez, J.M. 2008. Mortality due to snakebite envenomation in Costa Rica (1993–2006). *Toxicon* 52: 530-533.
- Giannotti, K.C.; Sesso, A.; Grego, K.F.; Fernandes, W.; Cardoso Jr, R.P.; Camargo, G.G. & Carneiro, S.M. 2013. Viperid venom glands with defective venom production. Morphological study. *Toxicon* 70: 32-43.
- Jiménez, M.; Saco, Y.; Pato, R.; Busquets, A.; Martorel, J.M. & Bassols, A. 2010. Plasma protein electrophoresis of *Trachemys scripta* and *Iguana iguana*. *Veterinary Clinical Pathology* 39: 227-235.
- Gómez, A.; Arroyo, C.; Astorga, W.; Chacón, D.; Rodríguez, S. & Jiménez, M. 2016. Hematological and biochemical reference intervals for *Bothrops asper* and *Crotalus simus* (Serpentes: Viperidae), maintained in captivity for venom extraction. *Comparative Clinical Pathology* 25: 615-623.
- Gutiérrez, J.M.; Lomonte, B.; Sanz, L.; Calvete, J.J. & Pla, D. 2014. Immunological profile of antivenoms: preclinical analysis of the efficacy of a polyspecific antivenom through antivenomics and neutralization assays. *Journal of Proteomics* 105: 340-350.
- Jackson, K. 2007. The evolution of venom-conducting fangs: insights from developmental biology. *Toxicon* 49: 975-981.
- Leenders, T. 2019. *Reptiles of Costa Rica; a field guide*. Hellbender Publishing; A Zona Tropical Publication.
- Lentini, A.M.; Crawshaw, G.J.; Licht, L.E. & McLelland, D.J. 2011. Pathologic and hematologic responses to surgically implanted transmitters in Eastern massasauga rattlesnakes (*Sistrurus catenatus catenatus*). *Journal of Wildlife Diseases* 47:107-125.
- Mackessy, S. 1991. Morphology and ultrastructure of the venom glands of the Northern Pacific Rattlesnake *Crotalus viridis oreganus*. *Journal of Morphology* 208: 109-128.
- Mader, D.R. 2006. *Reptile Medicine and Surgery*. Second Edition. Saunders; Elsevier. 1258 pp.
- Melillo, A. 2013. Applications of serum protein electrophoresis in exotic pet medicine. *Veterinary Clinics of North America: Exotic Animal Practice* 16: 211-225.
- Moreira, V.; Dos-Santos, M.C.; Nascimento, N.G.; Silva, H.B.; Fernandes, C.M. & D'Império-Lima, M.R. 2012. Local inflammatory events induced by *Bothrops atrox* snake venom and the release of distinct classes of inflammatory mediators. *Toxicon* 60:12-20.
- Rodríguez-Abarca, S.; Corrales, G.; Chacón, D.; Guevara, M.; Esquivel, C.; Arroyo, C. & Gómez, A. 2019. Morphological alterations caused by manual venom extraction on the main venom gland of *Bothrops asper* and *Crotalus simus* (Serpentes: Viperidae): long-term implications for antivenom production. *Toxicon* 172: 23-32.
- Sakai, F.; Carneiro, S.M. & Tamanouye, N. 2012. Morphological study of accessory gland of *Bothrops jararaca* and its secretory cycle. *Toxicon* 59: 393-401.
- Salakij, C.; Salakij, J.; Apibal, S.; Narkkong, N.A.; Chanhom, L. & Rochanapat, N. 2002. Hematology, morphology, cytochemical staining, and ultrastructural characteristics of blood cells in King cobras (*Ophiophagus hannah*). *Veterinary Clinical Pathology* 31: 116-126.
- Sasa, M. & Vázquez, S. 2003. Snakebite envenomation in Costa Rica: a revision of incidence in the decade 1990-2000. *Toxicon* 41:19-22.
- Silva, L.F.N.; Riani-Costa, C.C.M.; Ramos, P.R.R. & Takahira, R.K. 2011. Seasonal influence on biochemical profile and serum protein electrophoresis for *Boa constrictor amarali* in captivity. *Brazilian Journal of Biology* 71: 517-520.
- Stacy, N.I.; Alleman, A.R. & Sayler, K.A. 2011. Diagnostic Hematology of Reptiles. *Clinics in Laboratory Medicine* 31: 87-108.
- Teixeira, C.F.P.; Landucci, E.C.T.; Antunes, E.; Chacur, M. & Cury, Y. 2003. Inflammatory effects of snake venom myotoxic phospholipases A2. *Toxicon* 42: 947-962.
- Thrall, M.A.; Weiser, G.; Allison, R. & Campbell, T. 2012. In Thrall, M.A., Weiser, G., Allison, R., Campbell, T. (ed), *Veterinary Hematology and Clinical Chemistry*, 2nd ed, Wiley-Blackwell, England. p 259-276; 493-498.

A. Chang-Castillo *et al.* – Crotaline hematological and globulin profiles after surgery

Weber, R.E. & Campbell, K.L. 2011. Temperature dependence of haemoglobin–oxygen affinity in heterothermic vertebrates: mechanisms and biological significance. *Acta Physiologica* 202: 549-562.

Zaias, J. & Cray, C. 2002. Protein electrophoresis: a tool for the reptilian and amphibian practitioner. *Journal of Human Movement Studies* 12: 30-32.

© 2021 por los autores, licencia otorgada a la Asociación Herpetológica Argentina. Este artículo es de acceso abierto y distribuido bajo los términos y condiciones de una licencia Atribución-No Comercial 2.5 Argentina de Creative Commons. Para ver una copia de esta licencia, visite <http://creativecommons.org/licenses/by-nc/2.5/ar/>