

Lipomatous tumour in the endangered toad *Melanophryniscus montevidensis* (Anura: Bufonidae) from Uruguay

Emilia Rossini¹, Victoria Machín¹, Claudio Borteiro^{1,2}, Francisco Kolenc², José Manuel Verdes¹

¹ Departamento de Patología, Facultad de Veterinaria, Universidad de la República. Lasplaces 1550, Montevideo 11600, Uruguay.

² Sección Herpetología, Museo Nacional de Historia Natural, 25 de Mayo 582, Montevideo 11000, Uruguay.

Recibida: 28 Agosto 2018

Revisada: 29 Agosto 2018

Aceptada: 31 Agosto 2018

Editor Asociado: J. Goldberg

doi: 10.31017/CdH.2018.(2018-020)

ABSTRACT

We communicate the finding of a subcutaneous neoplasia in a female specimen of the toad *Melanophryniscus montevidensis* (Bufonidae) from Uruguay. The lesion extended from the cephalic to the abdominal region, and both gross and microscopic features were typical of lipomas. This is to our knowledge the fourth case reported in amphibians.

Key Words: Lipoma; Neoplasia; Amphibians

The study of skin-related tumours in amphibians constitutes a relevant issue in amphibian oncology (Balls and Clothier, 1974; Asashima *et al.*, 1987). Several types of neoplasia can affect the skin and subcutaneous tissue of these vertebrates, like papillomas, adenomas, adenocarcinomas, squamous cell carcinoma, chromatophoromas and also mesenchymatic tumours including lipomas (Schlumberger and Lucké, 1948; Balls, 1962; Berger *et al.*, 2004). Spontaneous tumours in wild amphibians are rarely reported, except for pollution-induced melanophoromas in salamanders of the genus *Ambystoma* (Rose and Harshbarger, 1977). In this note we communicate the finding of a lipomatous tumour in *Melanophryniscus montevidensis* (Bufonidae) in Uruguay. This toad is native to sandy coastal areas and associated lowland grasslands in southern Uruguay and eastern Argentina in Buenos Aires Province, as well as hilly environments of the latter, where habitat loss is of great concern for amphibians (Kolenc *et al.*, 2009; Baldo, *in Vaira et al.*, 2012).

An adult female of this species with a noticeable mass on the left side of cephalic region and trunk was captured in a field trip to Laguna de Rocha, Departamento de Rocha, southeastern Uruguay (34°38'21 S; 54°12'01 W, 48 m altitude). The toad was collected at a temporary pond during a reproductive episode, on February 21, 2018, and measured 28.3 mm of snout-vent length. It looked otherwise healthy, and did not exhibit abnormal behaviours

or postures. Its condition did not affect normal displacement. In the laboratory it was euthanized by cutaneous application of 20% benzocaine gel, and fixed with 10% formalin. Permits for capture and handling in the laboratory were issued by División Fauna – MGAP and Comité de Ética en el Uso de Animales of Facultad de Veterinaria, respectively. The lesion was dissected, and routinely processed for histological evaluation with hematoxylin and eosin staining (H&E); voucher number 18/225, in Departamento de Patología, Facultad de Veterinaria, Universidad de la República, Montevideo, Uruguay (FVET-UdelaR).

The protruding area that called our attention was more evident just posterior to the eye. Dissection of this lesion under a stereoscopic microscope showed a circumscribed structure of fat-like tissue and whitish colour, extending subcutaneously over the flank up to the posterior part of the abdomen (Fig. 1). At histological examination it consisted of a lipomatous tumour with a thin fibrous capsule. The capsule presented several fibrous attachments to the dermis and contiguous musculature (Fig. 2 A). The tissue forming the stroma of this neoplasia consisted mainly of typical adipocytes with moderate proliferation of blood vessels; some areas presented scattered chromatophores (presumably melanophores) and a small extent of fibrous tissue (Fig. 2 B). Both gross and microscopic characteristics of the lesion correspond to those of lipomas (Hendrick, 2017).



Figure 1. Lipoma in *Melanophryniscus montevidensis*. Arrows on the left indicate approximate boundaries of the tumour in the subcutaneous tissue of the cephalic region, which are evident externally; vertical one corresponds to its posterior limits.

Lipomas are benign and slow growing tumours (Hendrick, 2017), and their presentation in wild vertebrates seems to be sporadic. Particularly in amphibians there are only three previously published case reports, the first one is that of Reichenbach-Klinke and Elkan (1965) who describe this neoplasia associated to the urinary bladder in a toad *Bufo bufo* (Bufonidae). The other two known cases, like in the present study, correspond to single and circumscribed subcutaneous lipomas in *Xenopus laevis* (Pipidae; Balls, 1962) and *Melanophryniscus sanmartini* (Borteiro *et al.*, 2017). In these two reports the lipomas were approximately ovoid and relatively small masses located in the dorsum. As a difference, the lipoma in the present case largely extended over the flank. Similarly to the case in *M. sanmartini*, chromatophore cells were present but scarce.

Although the pathology of native toads of the genus *Melanophryniscus* has been scarcely studied (Langone and Maneyro, 1999; Borteiro *et al.*, 2017),

the frequency of neoplasias seems to be low (Borteiro, 2016). However, it is noteworthy that three of the four cases reported in amphibians correspond to bufonid species. Further data is needed to assess if bufonid toads present a particular predisposition to exhibit lipomas. Although benign, we are unaware about the possible deleterious effects of these expansile neoplasias by diminishing fitness in wild amphibians.

Acknowledgements

We thank Victoria Yozzi and Mayra Severo for their support at the laboratory of Departamento de Patología.

Literature cited

- Asashima, M.; Oinuma, T. & Meyer-Rochow, V.B. 1987. Tumors in Amphibia. *Zoological Science* 4: 411-425.
- Balls, M. 1962. Spontaneous neoplasms in Amphibia: a review and descriptions of six new cases. *Cancer Research* 22: 1142-1154.

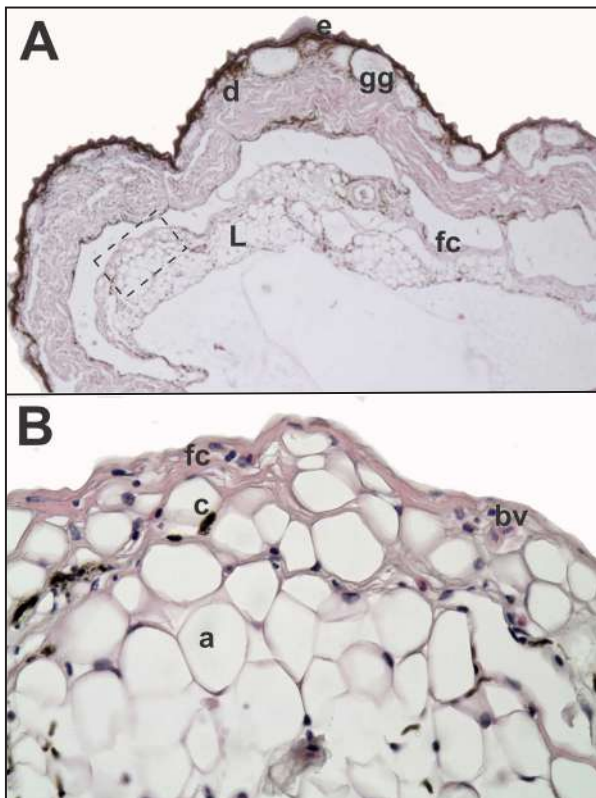


Figure 2. Subcutaneous lipoma in *Melanophryniscus montevidensis*. A, panoramic view of the tumour and the fibrous capsule containing it; histological section at the thoracic level (H&E, 100X). Dashed square corresponds to next figure. B, lipoma (L) at higher magnification (H&E, 400X). Other abbreviations: bv, blood vessel; c, chromatophores; d, dermis; e, epidermis; fc, fibrous capsule; gg, granular gland.

Balls, M. & Clothier, R.H. 1974. Spontaneous tumors in Amphibia. *Oncology* 29: 501-519.

Berger, L.; Speare, R. & Middleton, D. 2004. A squamous cell

carcinoma and an adenocarcinoma in Australian treefrogs. *Australian Veterinary Journal* 82: 96-98.

Borteiro, C. 2016. Enfermedades de la piel en anfibios de Uruguay y sureste de Brasil: nuevos diagnósticos y posibles efectos. PhD Thesis, PEDECIBA - Facultad de Ciencias, Universidad de la República, Montevideo.

Borteiro, C., Kolenc, F., Verdes, J.M., Martínez Debat, C. & Ubilla, M. 2017. Subcutaneous lipoma in the toad *Melanophryniscus sanmartini*, third case in amphibians. *Herpetology Notes* 10: 709-711.

Hendrick, M.J. 2017. Mesenchymal tumors of the skin and soft tissue: 142-175. In: Meuten, D.J. (ed.) *Tumors in domestic animals*. 5th ed., John Wiley & Sons, Ames, Iowa.

Kolenc, F.; Borteiro, C.; Baldo, D.; Ferraro, D. & Prigioni, C. 2009. The tadpoles and advertisement calls of *Pleurodema bibroni* Tschudi and *Pleurodema kriegi* (Müller), with notes on their geographic distribution and conservation status (Amphibia, Anura, Leiuperidae). *Zootaxa* 1969: 1-35.

Langone, J.A. & Maneyro, R. 1999. Malformaciones en los miembros en ejemplares del género *Melanophryniscus* de poblaciones uruguayas. *Publicación Extra, Museo Nacional de Historia Natural (Montevideo)* 50: 75.

Reichenbach-Klinke, H. & Elkan, E. 1965. *The principal diseases of lower vertebrates*. Academic Press, London & New York.

Rose, F.L. & Harshbarger, J.C. 1977. Neoplastic and possibly related skin lesions in neotenic Tiger salamanders from a sewage lagoon. *Science* 197: 315-317.

Schlumberger, H.H. & Lucké, B. 1948. Tumors of fishes, amphibians and reptiles. *Cancer Research* 8: 657-754.

Vaira, M.; Akmentins, M.S.; Attademo, M.; Baldo, D.; Barrasso, D.; Barrionuevo, S.; Basso, N.; Blotto, B.; Cairo, S.; Cajade, R.; Céspedes, J.; Corbalán, V.; Chilote, P.; Duré, M.; Falcione, C.; Ferraro, D.; Gutiérrez, F.R.; Ingaramo, M.R.; Junges, C.; Lajmanovich, R.; Lescano, J.N.; Marangoni, F.; Martinazzo, L.; Marti, R.; Moreno, L.; Natale, G.S.; Pérez Iglesias, J.M.; Peltzer, P.; Quiroga, L.; Rosset, S.; Sanabria, E.; Sánchez, L.; Schaefer, E.; Úbeda, C.; Zaracho, V. 2012. Categorización del estado de conservación de los anfibios de la República Argentina. *Cuadernos de Herpetología* 26(Supl. 1): 131-159.

© 2018 por los autores, licencia otorgada a la Asociación Herpetológica Argentina. Este artículo es de acceso abierto y distribuido bajo los términos y condiciones de una licencia Atribución-No Comercial 2.5 Argentina de Creative Commons. Para ver una copia de esta licencia, visite <http://creativecommons.org/licenses/by-nc/2.5/ar/>

